

Cutaneous Manifestations

This is a PDF version of the following document:

Module 2: [Basic HIV Primary Care](#)

Lesson 3: [Cutaneous Manifestations](#)

You can always find the most up-to-date version of this document at

<https://www.hiv.uw.edu/go/basic-primary-care/cutaneous-manifestations/core-concept/all>.

Introduction

Background

The spectrum of dermatologic conditions associated with HIV is vast. The skin is the largest and most visible organ of the body, and although the cutaneous immune system serves as the body's first line of defense against infection, it can also present numerous pathological manifestations.[1,2,3] Nearly all individuals with HIV will develop a skin disorder at some point in their clinical course, some of which can be debilitating and disfiguring; these conditions may present diagnostic challenges for clinicians and may incur significant medical costs for evaluation and treatment.[3]

Types of Lesions Based on Morphology

Skin disorders are a frequent reason for persons with HIV to seek medical care, and the dermatologic examination often provides valuable information about the person's immune status and may provide clues to the diagnosis of other systemic conditions. Skin lesions may be recognized based on morphological appearance, and the most common HIV-related lesions can be categorized into the following groups:

- **Abscess-Forming:** *Staphylococcus aureus* skin and soft tissue infections
- **Macular:** cutaneous drug reaction, acute (primary) HIV, primary and secondary syphilis infection
- **Nodular:** Kaposi's sarcoma, bacillary angiomatosis
- **Papular:** molluscum contagiosum, eosinophilic folliculitis, warts (condyloma acuminata), scabies
- **Scaling:** seborrheic dermatitis, psoriasis
- **Vesicular:** herpes simplex virus, mpox, varicella zoster virus

Bacillary Angiomatosis

Introduction

Bartonella species cause a wide range of clinical infections, including cat scratch disease, trench fever, retinitis, relapsing bacteremia, endocarditis, bacillary angiomatosis, and bacillary peliosis hepatis.[4,5] There are 24 *Bartonella* species, but only *B. henselae* and *B. quintana* cause significant disease infection among individuals with HIV. Transmission of *B. henselae* occurs via cat scratches and fleas (cats are the zoonotic reservoir), whereas *B. quintana* is transmitted primarily by lice and epidemiologically linked with homelessness (humans are the presumed reservoir). Bacillary angiomatosis typically occurs only in persons with HIV who have a CD4 count of less than 100 cells/mm³, and *Bartonella* infection can persist as a chronic infection for years in these immunosuppressed patients. In the current HIV era, *Bartonella* infection is rare.

Clinical Manifestations

Among persons with HIV, *Bartonella* infections show a predilection for the skin, liver, and spleen.[6] With severe immunosuppression, *Bartonella* infection can cause nodular, vascular skin lesions known as bacillary angiomatosis (Figure 1); these patients may also experience fever, culture-negative endocarditis, osteomyelitis, and other invasive manifestations.[7,8]

Diagnosis

A presumptive diagnosis of bacillary angiomatosis is often initially made based on clinical findings. Bacillary angiomatosis skin lesions can mimic many other conditions, including Kaposi's sarcoma, pyogenic granuloma, fibrosarcoma, and epithelioid sarcoma.[5,9] A definitive diagnosis requires either (1) a skin biopsy with a Warthin-Starry silver staining showing characteristic bacilli or (2) a polymerase chain reaction (PCR) positive for *Bartonella* on a tissue sample. An indirect fluorescent antibody (IFA) serologic test for *Bartonella* is available, and elevated antibody levels can suggest a diagnosis, but this assay has not been well validated for persons with HIV.[4] Isolating *Bartonella* species in culture is very difficult and generally requires the use of a special culture medium and prolonged incubation.

Treatment

All persons with HIV who are diagnosed with *Bartonella* infection should receive antimicrobial treatment. The following summarizes the Adult and Adolescent OI Guidelines recommendations for the treatment of bacillary angiomatosis.[4]

Preferred therapy for bacillary angiomatosis (Not for Endocarditis or CNS Infections):

- Doxycycline 100 mg PO or IV every 12 hours for at least 3 months (**AII**), or
- Erythromycin 500 mg every 6 hours for at least 3 months (**AII**)

Alternative Therapy for bacillary angiomatosis (Not for Endocarditis or CNS Infections):

- Azithromycin 500 mg PO daily (**BIII**), or
- Clarithromycin 500 mg PO twice daily (**BIII**)

Most infections can be treated with oral therapy, but severe infections may require intravenous and/or combination therapy.[4] If infection relapses after completing at least 3 months of primary treatment, then long-term suppressive therapy should be used as long as the individual's CD4 count is less than 200 cells/mm³. [4] There is no role for primary prophylaxis, though individuals with HIV (particularly those with low CD4 counts) may consider weighing the risks and benefits of cat ownership.[4]

Cutaneous Drug Eruptions

Introduction

Dermatologic complications secondary to adverse effects of medication can range from mild morbilliform reactions to life-threatening Stevens-Johnson syndrome and toxic epidermal necrolysis. Overall, individuals with HIV have an increased risk of developing severe cutaneous reactions compared to the general population. The proposed mechanisms for this increased risk are multiple, including greater medication usage in the population of persons with HIV compared to those without HIV, the use of high-dose trimethoprim-sulfamethoxazole therapy to treat *Pneumocystis pneumonia*, the presence of other infections, decreased antioxidant levels, and aberration of the hepatic cytochrome P450 system by direct viral effect.[10]

Clinical Manifestations

A wide clinical spectrum of skin rashes may be induced by antiretroviral medications, including abacavir, some protease inhibitors, and efavirenz (Figure 2).[11] These rashes include, but are not limited to, diffuse pruritic maculopapular eruption, diffuse urticaria, acute generalized erythematous pustulosis (AGEP), edema, hypersensitivity syndromes including drug rash with eosinophilia and systemic symptoms (DRESS). Certain classes of antiretrovirals are associated with particular types of reactions. Protease inhibitors, for instance, can cause a diffuse rash, whereas abacavir can cause hypersensitivity reactions involving both maculopapular rash and systemic symptoms. Medications such as trimethoprim-sulfamethoxazole and dapsone, which are used for prophylaxis and treatment of opportunistic infections, can also cause a skin rash. Stevens-Johnson syndrome is rarely seen in HIV clinical practice, but when it does occur, it is most often associated with a medication, such as trimethoprim-sulfamethoxazole, that contains a sulfa component.[3]

Diagnosis

The diagnosis of a cutaneous drug reaction relies heavily on a careful, complete patient history and also on the exclusion of other likely causes for rash (e.g. infectious, immunologic, allergic, and contact). In addition, with a diffuse body rash, it is always important to consider secondary syphilis in the differential diagnosis. The temporal sequence of drug and reaction is crucial, and withdrawal of the drug (followed by reintroduction of the drug in the case of more mild rashes) can provide important diagnostic clues. Biopsy is helpful mostly in excluding other etiologies for the rash. Of note, one potentially confounding factor is that some individuals with HIV who initiate antiretroviral therapy experience immune reconstitution inflammatory syndrome, a paradoxical worsening of previously diagnosed and/or unrecognized infections; many of the immune reconstitution inflammatory syndrome events that involve the skin may be confused for a cutaneous drug eruption.[11]

Treatment

Clinically stable patients with mild rash and an absence of systemic symptoms can often be managed with antihistamines. More severe symptoms require discontinuation of the drug and preclude reintroduction. In some severe cases, patients may require corticosteroids and possibly hospitalization. Patients who have a mild rash caused by trimethoprim-sulfamethoxazole can often successfully undergo desensitization at a later time. Clinicians should refer to the full prescribing information for each individual drug of concern, and referral to a dermatologist may be helpful for causes of unclear etiology or refractory symptoms after a medication is withdrawn.

Eosinophilic Folliculitis

Introduction

Eosinophilic folliculitis is a common skin disorder in individuals with HIV who have a CD4 count of less than 250 cells/mm³, but this cutaneous manifestation is uncommon in persons without HIV.[3] Although the pathogenesis of eosinophilic folliculitis remains unknown, available data suggest it likely develops as a result of a dysregulated immune response to common skin antigens or an underlying infection with *Pityrosporum ovale* or *Demodex* mites. Eosinophilic folliculitis is viewed as a marker of advancing immune suppression and sometimes is unmasked in the setting of immune reconstitution inflammatory syndrome.

Clinical Manifestations

Patients with eosinophilic folliculitis present with an intensely pruritic, erythematous papular rash with pinpoint pustules or vesicles centered around hair follicles on the face, upper chest and back, and/or upper arms (almost always above the nipple line).[12] The palms and soles are spared. Laboratory testing shows elevated serum IgE levels, eosinophilia, and leukocytosis.

Diagnosis

The diagnosis of eosinophilic folliculitis is usually suspected based on the finding of intensely pruritic perifollicular lesions in the appropriate clinical setting, but it may be very difficult to distinguish from bacterial folliculitis and pruritic papular eruption.[12,13] Skin biopsy performed for diagnostic confirmation will show an intense perivascular and diffuse inflammatory infiltration that includes eosinophils, lymphocytes, histiocytes, mast cells, and neutrophils.

Treatment

For persons with eosinophilic folliculitis who are not receiving antiretroviral therapy, the initiation of antiretroviral therapy is an important component of treatment and this condition typically improves with effective antiretroviral therapy. In some instances, the rash may transiently worsen after starting antiretroviral therapy due to immune reconstitution inflammatory syndrome. Topical corticosteroids, combined with antihistamines or the antidepressant doxepin, are also usually used in the short-term management of eosinophilic folliculitis.[14]

Herpes Simplex Virus

Introduction

In the United States, among persons 14 through 49 years of age, 47.8% are seropositive for herpes simplex type 1 (HSV-1), and 11.9% are seropositive for HSV-2.[15] Among persons with HIV, infection with HSV occurs frequently, and more than 95% of individuals with HIV are seropositive for either HSV-1 or HSV-2.[16] Either HSV-1 or HSV-2 can cause genital herpes.[17,18,19] Recurrent HSV is a chronic infection characterized by periodic reactivation, during which shedding from orolabial and genital mucosal surfaces is increased; shedding can occur even when patients are asymptomatic, and HSV shedding also persists despite antiretroviral therapy among persons with HIV and HSV coinfection.[20] When compared with persons without HIV, those with HIV tend to have more severe and chronic HSV lesions, with more asymptomatic shedding of HSV-2 in the genital tract, particularly in persons with lower CD4 cell counts. Furthermore, HSV-2 reactivation, including asymptomatic shedding without clinically apparent lesions, can increase the rates of HIV transcription, resulting in increased HIV levels in both plasma and genital tissues.[21,22,23]

Clinical Manifestations

Cutaneous infection with HSV-1 most often manifests with lesions of the mouth and lips, and HSV-2 more commonly causes genital lesions, though HSV-1 and HSV-2 can cause lesions anywhere on the body and are indistinguishable from a clinical perspective. Further, HSV-1 has been increasingly associated with anogenital infection, and in some populations, such as young men who have sex with men and young heterosexual women, HSV-1 now accounts for the majority of first-episode anogenital herpes.[17,18,24] Regardless of the site, most people with cutaneous HSV experience a sensory prodrome followed by an evolution of the lesion(s) from papule to vesicle to crusting stage.[16] If untreated, most individuals will have symptoms that persist for 5 to 10 days; anti-herpes therapy initiated at the onset of the prodrome can shorten the symptomatic period or even abort the outbreak. Persons with a CD4 count of less than 100 cells/mm³ often have chronic, deep, extensive, non-healing ulcers that can occur anywhere on the body, including the face, ears, and genital tract (Figure 3).[16,25] In addition, persons with HIV who have just started effective antiretroviral therapy may develop unusual ulcerative lesions as a manifestation of immune reconstitution syndrome.[25]

Diagnosis

The diagnosis of HSV can be difficult on a clinical basis alone, and lesions can mimic other infections. Diagnosis, therefore, should be pursued through laboratory testing. Herpes simplex virus DNA PCR testing is the most sensitive method for establishing the diagnosis; viral culture and antigen detection are other options.[19,26] Serologic testing using an IgG-based assay may be helpful for persons with HIV who present with lesions for the first time (to confirm primary infection).

Treatment

Treating Initial Genital Lesions or Recurrent Genital Lesions

The Adult and Adolescent OI Guidelines recommend treatment of cutaneous HSV with oral valacyclovir, famciclovir, or acyclovir for 5 to 10 days; intravenous acyclovir may be required for severe mucocutaneous disease and/or disseminated disease (Table 1).[16] Persons with HIV may opt for episodic treatment or daily suppressive therapy if they experience frequent or severe outbreaks.[16] Primary prophylaxis for herpes simplex is not recommended, regardless of HIV serostatus.

Suppressive Therapy

Numerous studies have shown that suppressive therapy of HSV-2 reduces HIV-1 levels in both the plasma and

genital tract and prevents HIV disease progression, but these studies were in persons who were not receiving HIV antiretroviral therapy.[27,28] Suppressive therapy of HSV-2 in persons with HIV has not been shown to decrease the risk of transmission of either HSV or HIV to a sex partner.[29,30,31] In addition, among persons with HIV and HSV-2 coinfection (who are taking suppressive antiretroviral therapy), adding daily oral valacyclovir did not significantly change any primary or secondary immunological outcomes.[32] The following table summarizes indications and regimens for suppressive anti-HSV therapy in people with HIV.[16] (Table 2)

Acyclovir-Resistant HSV

Acyclovir-resistant HSV in persons with HIV is associated with advanced immunosuppression and more frequent use of anti-HSV drugs, with episodic therapy posing a greater risk than suppressive therapy.[33,34] Acyclovir-resistant HSV often presents as destructive chronic ulcerative lesions (Figure 4).[35] Acyclovir resistance should be suspected if there is no clinical improvement after 7 to 10 days of appropriate HSV treatment; if this occurs, a sample from the lesion should be sent for viral culture with drug susceptibility testing (if HSV is isolated). The activation of acyclovir depends on an initial phosphorylation step performed by viral thymidine kinase; the most common mechanism of acyclovir resistance is absent or decreased production of thymidine kinase by HSV (Figure 5).[36,37,38] Foscarnet inhibits viral DNA replication directly and does not require phosphorylation by viral thymidine kinase. The following summarizes recommendations from the Adult and Adolescent OI Guidelines for the treatment of acyclovir-resistant HSV.[16]

- **Preferred Treatment:** The preferred treatment is intravenous foscarnet 80 to 120 mg/kg/day divided into two or three daily doses until clinical improvement.[16,37,39] Foscarnet can cause significant adverse effects, including renal insufficiency and electrolyte abnormalities.
- **Alternative Therapy (given for 21 to 28 Days, Based on Clinical Response):** Alternative therapy options include intravenous cidofovir 5 mg/kg given once weekly; topical ophthalmic trifluridine 1% given three times a day; topical cidofovir 1% gel given once daily, topical imiquimod 5% cream given three times a week, or topical foscarnet 1% given five times a day.[16]

Kaposi's Sarcoma

Introduction

Kaposi's sarcoma is a vascular tumor caused by human herpes virus-8 (HHV-8), also known as KS-associated herpes virus (KSHV). Kaposi's sarcoma is an AIDS-defining condition that was very common among men during the first two decades of the HIV epidemic.[40,41,42] The prevalence of Kaposi's sarcoma dramatically declined with the widespread availability of effective antiretroviral therapy, though the disease continues to cause substantial morbidity and mortality.[43] Among individuals with HIV in the United States, Kaposi's sarcoma has a peak incidence among men who have sex with men aged 25 to 59 years.

Clinical Manifestations

Kaposi's sarcoma skin lesions have a varied presentation but tend to progress through three stages: patch, plaque, and nodular. The lesions may be discrete or confluent and tend to appear in a symmetrical distribution. The lesions can vary in color (brown, pink, red, violaceous) and in size (millimeters to several centimeters in diameter), though nearly all will be palpable and non-pruritic (Figure 6). The lesions may develop anywhere on the body, including the face, torso, extremities, and genital tract. Initially, the lesions do not cause problems, but they may expand and cause severe local edema and lymphatic obstruction. Extracutaneous spread to mucous membrane involvement can occur, and some patients may develop visceral organ involvement (gastrointestinal, pulmonary, lymphatic).[44]

Diagnosis

A definitive diagnosis of Kaposi's sarcoma requires biopsy of the cutaneous lesion(s). Classic findings on pathology include neovascularization with aberrant proliferation of small vessels, atypical spindle-shaped cells with leukocytic infiltration, and hemosiderin-laden macrophages.

Treatment

The treatment for Kaposi's sarcoma depends on the severity of the disease and whether there is any evidence for visceral organ disease.

- **Antiretroviral Therapy:** Suppressive antiretroviral therapy is recommended for all persons who have AIDS-related Kaposi's sarcoma, and it often causes regression of lesions without the need for additional treatment.[41,45] Early studies suggested a direct anti-angiogenesis effect from protease inhibitors and led many clinicians to advocate for their use in the treatment of Kaposi's sarcoma, but further studies have shown that the effects of antiretroviral therapy are mediated by immune restoration rather than by direct antitumor effects.[41]
- **Treatment for Localized Disease:** When indicated, treatment for localized disease may involve radiation, intralesional chemotherapy, topical therapy, or surgical excision.[44]
- **Cytotoxic Chemotherapy:** Systemic cytotoxic chemotherapy is reserved for treatment of severe or disseminated disease, and adding chemotherapy to antiretroviral therapy in these patients reduces disease progression compared to antiretroviral therapy alone.[46]
- **Antiviral Agents:** Several antiviral agents including foscarnet, cidofovir, and ganciclovir show in vitro activity against HHV-8 but are ineffective in treating Kaposi's lesions, likely because they inhibit lytic rather than latent viral replication (and most HHV-8 in Kaposi's sarcoma cells are in the latent phase).

MRSA Skin and Soft Tissue Infections

Introduction

Staphylococcus aureus, including methicillin-sensitive and methicillin-resistant strains, is a common cause of skin infections for persons with HIV.[1,47] People with HIV have rates of community-acquired MRSA infections that are 6- to 18-fold higher than among persons without HIV.[48,49,50] In addition, persons with HIV experience more serious infections with more frequent recurrences.[51] Some studies show that the incidence peaked in 2007 and has now stabilized, but MRSA infections continue to cause a significant burden of disease among persons with HIV. Other factors, such as injection drug use and multiple sex partners, may play a role in MRSA transmission.[51,52] As in the general population, the most common strain causing infection is the USA-300 strain.

Clinical Manifestations

The most frequent clinical presentation of MRSA is localized skin and soft tissue infection with a furuncle, abscess, or cellulitis; skin infections may mimic bite wounds, particularly spider bites (Figure 7). Invasive infections, including pneumonia, septic pulmonary emboli, osteomyelitis, meningitis, and endocarditis, can also occur.

Diagnosis

The most accurate method for the detection of MRSA is culture of a clinical sample with use of a polymerase chain reaction probe to detect the *mecA* gene in a microbiologic sample growing staphylococcus, but traditional microbiology lab techniques (using oxacillin-salt agar screening plates or ceftaxime disk diffusion tests) and rapid culture techniques are also available. Antimicrobial susceptibility testing should be performed on MRSA isolates.

Treatment

Primary management in the outpatient setting involves incision and drainage of the abscess, and some patients will improve with local therapy alone, particularly if the entire infected area is completely drained. The Infectious Diseases Society of America recommends the addition of antibiotics with the following conditions: severe or extensive disease or rapid progression in the setting of associated cellulitis, associated comorbidities or immunosuppression, extremes of age, or in the case of difficult-to-drain abscesses or lack of response to incision and drainage.[53] Anti-MRSA oral antibiotic therapy includes trimethoprim-sulfamethoxazole (1-2 double-strength tablets twice daily), doxycycline (100 mg twice daily), clindamycin (300 to 450 mg four times daily), and linezolid (600 mg twice daily).[53] Most experts prefer trimethoprim-sulfamethoxazole, unless the patient has a sulfa allergy. Duration of antibiotic treatment is typically 5 to 10 days but should be guided by the severity of the infection and by clinical response to therapy.

Molluscum Contagiosum

Introduction

Molluscum contagiosum, caused by the large double-stranded molluscum contagiosum virus (MCV) belonging to the *Poxviridae* family, is a common skin disorder in the general population, manifesting as pearly flesh-colored papules with central umbilication. Between 5 and 18% of persons with HIV not on antiretroviral treatment will develop molluscum contagiosum at some point, with higher rates seen among individuals with a CD4 count of less than 200 cells/mm³.^[54] Molluscum contagiosum is often more extensive and refractory to therapy in persons with HIV who have very low CD4 cell counts.

Clinical Manifestations

In persons with HIV, the cutaneous manifestations of molluscum contagiosum vary from typical umbilicate papular lesions to large, disfiguring, wart-like growths (Figure 8).^[55] Typical lesions of molluscum contagiosum usually appear as small, discrete, waxy, flesh-colored papules averaging 3 to 5 mm in diameter, often with a central umbilication. In immunocompetent hosts, the number of lesions is generally fewer than 20. In persons with HIV who have advanced immunosuppression, the lesions are usually numerous and characteristically involve the face and genital region. With advanced immunosuppression, the lesions may be irregular in shape, lack a central umbilication, and coalesce into larger disfiguring lesions, often referred to as giant molluscum. In some instances, the lesions can coalesce into disfiguring wart-like papular lesions.

Diagnosis

The diagnosis of molluscum contagiosum is primarily based on clinical appearance but can be confirmed with skin biopsy; histologic examination using hematoxylin and eosin staining characteristically reveals keratinocytes with eosinophilic intracytoplasmic inclusion bodies called molluscum bodies (or Henderson-Patterson bodies) (Figure 9).^[56] If necessary, the viral material can be extruded from the ostium of the molluscum contagiosum lesion and will show brick-shaped poxvirus particles under electron microscopy.^[57]

Treatment

Initiation of antiretroviral therapy is the mainstay of treatment for molluscum contagiosum in persons with HIV—effective, sustained suppression of plasma HIV RNA levels is usually sufficient to cause regression of the lesions, although immune reconstitution inflammatory syndrome can temporarily cause a paradoxical worsening of the condition.^[58,59,60,61] If the lesions of molluscum contagiosum persist despite the use of antiretroviral therapy, localized treatments can be used, including cryotherapy, curettage, pulsed dye laser therapy, and immune modulators, such as topical imiquimod. In general, antiviral therapy is more effective than ablative therapies.^[57]

Psoriasis

Introduction

Psoriasis occurs with similar frequency in persons with or without HIV, but people with HIV and advanced immunosuppression are more likely to develop severe psoriasis, treatment-refractory disease, and psoriatic arthritis.[3] The pathogenesis of psoriasis in persons with HIV is unclear but may involve immune dysregulation, alteration of CD8:CD4 ratio, and/or viral molecular mimicry whereby the virus “mimics” the host cells and causes an inappropriate cross-reaction, thus inducing autoimmunity.

Clinical Manifestations

In the general population, persons with psoriasis commonly present with symmetrical, salmon-colored plaques with silver scales on extensor surfaces. In contrast, persons with HIV typically present with guttate, inverse, and erythrodermic psoriasis.[62] Guttate psoriasis presents as multiple, small (less than 1 cm) lesions primarily involving the trunk. Inverse psoriasis refers to plaques in the intertriginous areas. Erythrodermic psoriasis is characterized by full-body erythema and scaling (Figure 10). Due to the widespread breakdown of the skin barrier, these individuals are at increased risk of secondary skin infection and electrolyte imbalance. One of the hallmark features of psoriasis in persons with HIV is the simultaneous development of several morphological types.[63] Many individuals with HIV who have psoriasis will also have joint pain, stiffness, and effusion in the distal interphalangeal joints and spine due to psoriatic arthritis.

Diagnosis

The diagnosis of psoriasis is made based on clinical appearance and, if necessary, can be confirmed by biopsy. Classic histopathologic findings include amplified proliferation of basal keratinocytes, premature desquamation of the stratum corneum, neutrophils in the stratum corneum, and dilated capillaries in the dermis.[63]

Treatment

Treatment of psoriasis is challenging in persons with HIV because HIV-associated psoriasis is a T-lymphocyte mediated disease that occurs in the setting of T-lymphocyte depletion.[62] Ideally, a dermatologist should manage or provide expert consultation for persons with HIV who have severe psoriasis. Effective antiretroviral therapy often causes improvement in psoriasis and may be sufficient to treat psoriasis, particularly in mild cases.[64] Additional therapy depends on the severity of psoriasis, which is typically gauged by the total body surface area involved.[62] Options for additional therapy include topical steroids, topical vitamin D analogs, retinoids (topical and oral), topical phosphodiesterase-4 inhibitors (topical and oral), tar, ultraviolet light therapy, oral retinoids, cyclosporine, methotrexate, and multiple biologic agents, including TNF-alfa inhibitors, inhibitors of IL-17 pathway, and inhibitors of IL-23 and related cytokines. Cyclosporine, methotrexate, and biologic agents can all potentially increase the risk of infection, and thus, these agents should be reserved for severe disease and require careful monitoring.[62]

Scabies

Introduction

Scabies is caused by an ectoparasite, *Sarcoptes scabiei* (Figure 11). Transmission typically requires prolonged skin-to-skin contact with the exception of crusted (Norwegian) scabies, which is a severe and highly contagious form of infection that can be transmitted via an airborne route in nosocomial settings to other patients and health workers.[65,66,67] Crusted scabies is associated with severe immunosuppression and is also seen in patients with debilitation and malnourishment; these individuals may be more susceptible to the more severe crusted form of scabies as a result of deficient host immunity as well as a decreased scratching reflex (since scratching is actually an effective way to reduce the number of mites). There are case reports of crusted scabies presenting as a manifestation of immune reconstitution inflammatory syndrome in persons with HIV.[68]

Clinical Manifestations

Scabies infections cause intense pruritus. The initial skin lesions are small erythematous papules that can evolve into vesicles or bullae, though the hallmark clinical finding is a thin, short, wavy burrow; scabies lesions have a predilection for certain areas of the body, such as the interdigital space of the fingers, the flexor aspects of the wrist, the axilla, the lateral and plantar aspects of the feet, and the external genitalia, buttocks, and thighs.[69] Papules may be seen in the genital region. Crusted scabies typically manifests as plaques that develop a prominent scale with crusts and fissures, resembling psoriasis; when crusted scabies involves the scalp, it can mimic severe scalp seborrheic dermatitis (Figure 12).[70] Secondary bacterial infection is common due to skin excoriations.

Diagnosis

A presumptive clinical diagnosis can be made in patients who present with intense itching (especially at night), a burrow at a typical site, and household or sexual contact with another individual with scabies. Skin scrapings can yield specimens that show mites and eggs (Figure 13); occasionally, a skin biopsy may be required in a person who has an atypical presentation. A skin biopsy will typically not yield evidence of mites but will show a nonspecific, delayed hypersensitivity reaction.[69] With crusted scabies, abundant mites are present and easily identified with a skin scraping.

Treatment

- **Scabies:** Patients with scabies and their close household and sexual contacts should be treated at the same time, regardless of symptoms. The most effective therapy is topical permethrin 5% cream (usually only a single application from the neck down is required); permethrin should be washed off 8 to 14 hours after it is applied.[71,72] Oral ivermectin, 200 mcg/kg as a single dose and repeated again 10 to 14 days later, can be used in persons who do not respond to topical therapy and may be considered for first-line therapy in patients with generalized eczema or who are unable to adhere with topical therapy.[69,72,73] The rash and pruritus caused by scabies can persist for up to 2 weeks after treatment.
- **Crusted Scabies:** There have been no controlled trials for the treatment of crusted scabies, but the Centers for Disease Control and Prevention (CDC) recommends combined treatment with a topical scabicide plus oral ivermectin 200 mcg/kg given on days 1, 2, 8, 9, 15, and possibly on days 22 and 29; individuals with HIV who have crusted scabies should be managed in conjunction with expert consultation.[72]
- **Nonpharmacologic Measures:** Regardless of pharmacotherapy, patients with crusted scabies should wash bed linens and clothing in hot water (ideally with a scabicide lotion) or place them into a hermetically sealed bag for several days.[70]

Seborrheic Dermatitis

Introduction

Seborrheic dermatitis is a common clinical skin manifestation that affects 34 to 83% of persons with HIV, as opposed to 1 to 3% of the general population.[3] This condition is both more frequent and more severe in patients with advanced immunosuppression.[74] Seborrheic dermatitis in persons with HIV is likely due to a dysregulated immune response to fungal skin pathogens, such as *Malassezia* species.

Clinical Manifestations

Seborrheic dermatitis develops on the face, beard, nasolabial fold, scalp, eyebrows, ears, and upper chest, manifesting as flaky, scaling, erythematous patches or plaques; the lesions may have a greasy appearance and have a white or yellowish scale on the surface (Figure 14).[75] Patients with HIV and advanced immunosuppression may have more diffuse involvement, sometimes affecting the scalp and extremities. Because seborrheic dermatitis has been linked to depression in T-cell function, worsening seborrheic dermatitis can be used as a marker of HIV disease progression.[3]

Diagnosis

The diagnosis of seborrheic dermatitis is primarily based on typical clinical findings and, if necessary, can be confirmed with a biopsy. Histopathologic findings may include widespread parakeratosis, spotty keratinocytic necrosis, leukocytosis, and a superficial perivascular infiltrate of plasma cells and neutrophils; these sections also show expression of certain heat-shock proteins, which does not occur among individuals without HIV.[3]

Treatment

Antifungal drugs, including ketoconazole, itraconazole, and terbinafine, are the mainstay of treatment and can be delivered in shampoos, creams, or oral medications. Intermittent use of antifungals can maintain remission, and topical corticosteroids may be useful in the short term to control erythema and itching.[75] Persons with HIV who start antiretroviral therapy often have major improvement or regression of seborrheic dermatitis.[76]

Herpes Zoster

Introduction

Adults with HIV have an increased risk for varicella-zoster virus reactivation disease (herpes zoster, also known as shingles). Before the widespread use of highly effective antiretroviral therapy and herpes zoster vaccines, the incidence of zoster among adults with HIV was at least 15-fold higher than among age-matched immunocompetent adults, and the risk is highest among persons with HIV who have a CD4 count of less than 200 cells/mm³.[\[77,78,79\]](#) Individuals with HIV may have an additional increased risk of developing herpes zoster in the first 4 months after starting effective antiretroviral therapy, likely as a result of immune reconstitution.[\[80\]](#) In contrast, long-term use of suppressive antiretroviral therapy reduces the risk of developing zoster in persons with HIV.[\[81\]](#)

Clinical Manifestations

Herpes zoster is characterized by a prodrome of dysesthesias for several days before the onset of cutaneous lesions. The lesions appear as a cluster of vesicles on an erythematous base, and they may coalesce into larger bullae ([Figure 15](#)). Zoster characteristically follows a dermatomal distribution, most commonly affecting the skin of the thorax. Complications of dermatomal zoster include scarring, bacterial superinfection of the lesions, severe necrotic zoster, and postherpetic neuralgia, which is manifested as severe skin pain in the same distribution as the original lesions but occurring after resolution of the lesions. People with HIV have a two-fold increase in the risk of developing postherpetic neuralgia when compared to persons without HIV.[\[82\]](#) Trigeminal nerve involvement, also referred to as herpes zoster ophthalmicus, can potentially lead to a multitude of eye-related complications. Individuals with HIV and advanced immunosuppression are at increased risk of disseminated herpes zoster infection, including ocular, central nervous system, or visceral organ involvement.

Diagnosis

The diagnosis of herpes zoster is usually based on a characteristic clinical presentation, but if needed, the diagnosis can be confirmed by obtaining a swab of a fresh (non-crusted) lesion and testing with polymerase chain reaction (PCR), direct fluorescent antibody (DFA), or culture. [\[77\]](#) To collect the sample for DFA testing, unroof the lesion and scrape the base, since this optimizes the collection of more cellular material. Although viral culture has been the gold standard for diagnosis, there is increasing evidence that it is suboptimal when compared with more modern molecular techniques, such as PCR.[\[26\]](#) If the lesions are already crusted, the sensitivity of any test is decreased, but in this situation, PCR testing provides the highest yield.[\[77\]](#)

Treatment

- **Uncomplicated Cutaneous Zoster:** The preferred treatment for herpes zoster in persons with HIV is oral therapy with either valacyclovir or famciclovir for 7 to 10 days; oral acyclovir is considered an alternative treatment ([Table 3](#)).[\[77\]](#) The five times a day dosing required for acyclovir is difficult from a practical standpoint, and most clinicians use valacyclovir or famciclovir, both of which require three times daily dosing.[\[77\]](#) Ideally, treatment should be initiated within 72 hours of symptom onset, though there is evidence that treatment beyond this window may still be effective in immunocompromised adults.[\[83\]](#)
- **Severe or Disseminated Zoster:** In cases with severe and/or disseminated disease, including ocular, otic, or with neurological complications, intravenous acyclovir may be required.
- **Adjunctive Therapy:** Corticosteroids are sometimes recommended as an adjuvant therapy for adults with zoster who do not have HIV, but due to a lack of data and a theoretical risk of causing immunosuppression, corticosteroids should not be used as a component of therapy for treating zoster in persons with HIV.
- **Acyclovir-Resistant VZV:** Intravenous foscarnet (100 mg/kg twice daily) for 14 to 21 days can be

used in the rare instances of acyclovir-resistant varicella zoster infection.[84]

- **Pain Control:** Pain control is an important aspect of treating active varicella and zoster infections, and treatment may involve a combination of opiates, gabapentin, tricyclic antidepressants, and topical capsaicin.

Prevention

- **Zoster Vaccine:** The Adult and Adolescent OI Guidelines recommend giving two doses (2 to 6 months apart) of the recombinant zoster vaccine (RZV) to all persons with HIV who are 18 years of age or older, regardless of CD4 cell count.[77] The zoster vaccine should not be administered in the setting of an acute episode of herpes zoster.[77]
- **Postexposure Prophylaxis:** In the event that an individual is nonimmune to varicella and experiences a significant exposure to either active varicella or zoster, varicella-zoster immune globulin (VZIG) should be administered within 96 hours.[85] Unfortunately, access to VZIG is limited; if it is unavailable, then it is reasonable to administer valacyclovir (1 gram three times daily) on postexposure days 3 to 22.[77,86] There are no recommendations for administering chronic suppressive anti-herpes medications to prevent zoster.

Warts (Anogenital)

Introduction

Anogenital warts, also called condyloma acuminata, are the most common viral sexually transmitted infection and the most common wart observed in persons with HIV. These warts are caused by the ubiquitous human papillomaviruses (HPV), which are small double-stranded DNA viruses that can be categorized into cutaneous and mucosal groups. Most sexually active adults will acquire HPV infection at some point in their lives, and, in most cases, the virus is cleared spontaneously. More than 100 types of HPV have been identified, and the nononcogenic types 6 and 11 cause approximately 90% of anogenital warts.^[87] Among individuals with HIV, lesions may also be more recalcitrant to therapy due to deficient cell-mediated immunity. Although effective antiretroviral therapy has not been proven to reduce the risk of developing anogenital warts, higher CD4 counts and lower HIV RNA levels seem to independently reduce the risk of acquiring warts.^[88]

Clinical Manifestations

Typical condyloma acuminata are flesh-colored and can range from smooth, flattened lesions to verrucous papules. Most patients are asymptomatic, but some with extensive or multiple lesions may complain of pain, burning, or pruritus.

Diagnosis

The diagnosis of condyloma acuminata is typically made by visual inspection. The diagnosis of genital warts can be confirmed by biopsy.

Treatment

Recommended treatment options for external anogenital warts include chemical or physical destruction, immunologic therapy, and surgical therapy. Regardless of the treatment method, recurrence rates are high, especially in the first three months after treatment.^[89] As outlined in the 2021 STI Treatment Guidelines, the general approach to the treatment of anogenital warts is the same for persons with or without HIV; these recommended options include patient-applied and provider-administered treatments.^[89]

2021 STI Treatment Guidelines: Anogenital Warts

Table 4. Treatment of External Anogenital Warts

External anogenital warts include penis, groin, scrotum, vulva, perineum, external anus, and perianus*

Recommended **for PATIENT-APPLIED Therapy**

Imiquimod 3.75% cream

Imiquimod 3.75% cream

Tradename:Zyclara

Apply the 3.75% cream once at bedtime, every night consecutively for up to 8 weeks.

The treatment area should be washed with soap and water 6-10 hours after the application.

Note: The imiquimod cream might weaken condoms and vaginal diaphragms.

Recommended **for PATIENT-APPLIED Therapy**

Imiquimod 5% cream

Imiquimod 5% cream

Tradename:Aldara

Apply the 5% cream once at bedtime, three times a week for up to 16 weeks.

The treatment area should be washed with soap and water 6-10 hours after the application.

Note: The imiquimod cream might weaken condoms and vaginal diaphragms.

Recommended **for PATIENT-APPLIED Therapy**

Podofilox 0.5% solution or gel

Podofilox 0.5% solution or gel

Tradename:Condylox

Apply podofilox solution (using a cotton swab) or podofilox gel (using a finger) to anogenital warts twice a day for 3 days, followed by 4 days of no therapy. Repeat the cycle, as necessary, for up to four cycles.

The total wart area treated should not exceed 10 cm², and the total volume of podofilox should be limited to 0.5 mL per day.

Recommended **for PATIENT-APPLIED Therapy**

Sinecatechins 15% ointment

Sinecatechins 15% ointment

Tradename: Veregen

Apply three times daily (0.5 cm strand of ointment to each wart) using a finger to ensure coverage with a thin layer of ointment until complete clearance of warts is achieved. This product should not be continued for longer than 16 weeks.

Do not wash off after use.

Note: Sinecatechins might weaken condoms and vaginal diaphragms.

Recommended **for PROVIDER-ADMINISTERED Therapy**

Cryotherapy with liquid nitrogen or cryoprobe

Cryotherapy with liquid nitrogen or cryoprobe

Tradename:

Local anesthesia (topical or injected) might facilitate therapy if warts are present in many areas or if the area of warts is large.

Note: Health care providers should be trained on the proper use of this therapy because over- and under-treatment can result in complications or low efficacy.

Recommended **for PROVIDER-ADMINISTERED Therapy**

Surgical removal either by tangential scissor excision, tangential shave

Surgical removal either by tangential scissor excision, tangential shave

Tradename:

After local anesthesia is applied, anogenital warts can be physically destroyed by electrocautery, in which case no additional hemostasis is required. Alternatively, the warts can be removed either by tangential excision with a pair of fine scissors or a scalpel, by carbon dioxide (CO₂) laser, or by curettage.

Note: Surgical therapy has the advantage of eliminating most warts at a single visit, although recurrence can

occur. Surgical removal requires substantial clinical training, additional equipment, and sometimes a longer office visit.

Recommended **for PROVIDER-ADMINISTERED Therapy**

Trichloroacetic acid (TCA) or Bichloroacetic acid (BCA) 80-90% solution

Trichloroacetic acid (TCA) or Bichloroacetic acid (BCA) 80-90% solution

Tradename:

A small amount should be applied only to the warts and allowed to dry (i.e. develop white frost on tissue) before the patient sits or stands.

If pain is intense or an excess amount of acid is applied, the area can be covered with sodium bicarbonate (i.e., baking soda), washed with liquid soap preparations, or be powdered with talc to neutralize the acid or remove unreacted acid. TCA or BCA treatment can be repeated weekly if necessary.

Note: TCA solution has a low viscosity comparable with that of water and can spread rapidly and damage adjacent tissues if applied excessively.

*Persons with external anal or perianal warts might also have intra-anal warts. Thus, persons with external anal warts might benefit from an inspection of the anal canal by digital examination, standard anoscopy, or high-resolution anoscopy.

Source: Workowski KA, Bachmann LH, Chan PA, et al. Sexually transmitted infections treatment guidelines, 2021. Human papillomavirus (HPV) infection: anogenital warts. MMWR Recomm Rep. 2021;70(No. RR-4):1-187. [[2021 STI Treatment Guidelines](#)]

Courtesy of [National STD Curriculum](#).

Prevention

The 9-valent HPV vaccine (9vHPV) is now the only HPV vaccine manufactured in the United States, and it has been approved by the FDA for use in males and females ages 9 through 45 years.[[90](#)] This vaccine contains HPV 6 and 11, which together cause approximately 90% of anogenital warts. In addition, the 9vHPV vaccine protects against the dominant anogenital cancer types HPV 16 and 18, as well as 5 other subtypes that cause a minority of HPV anogenital cancers. The Adult and Adolescent OI Guidelines recommend HPV vaccination for individuals with HIV aged 9 through 26 years.[[87](#)] The 9vHPV vaccine is not routinely recommended for persons with HIV who are older than 26 years of age, but it can be considered in this age group using a shared decision-making process.[[87](#)] This recommendation is based on a study in persons with HIV older than age 26 that found HPV vaccination did not prevent new anal HPV infections or improve outcomes for persons with anal high-grade squamous intraepithelial (HSIL) lesions.[[91](#)]

Summary Points

- *Bartonella* infection, though rare in the current HIV era, can cause nodular, vascular skin lesions known as bacillary angiomatosis in persons with HIV.
- Persons with HIV have a significantly elevated risk of developing severe cutaneous reactions compared to the general population. Stevens-Johnson syndrome is seen most often in patients taking multidrug regimens containing a sulfa component or nevirapine.
- Eosinophilic folliculitis causes an intensely pruritic, erythematous papular rash (almost always above the nipple line) with pinpoint pustules or vesicles. Eosinophilic folliculitis ultimately improves with effective antiretroviral therapy but often initially worsens due to immune reconstitution inflammatory syndrome.
- Herpes simplex virus infections are common among individuals with HIV and can be treated effectively with acyclovir, valacyclovir, or famciclovir. Suppressing antiviral therapy for HSV reduces the frequency of outbreaks of HSV-2 genital ulcers, but it has not been found to reduce the risk of transmission of either HIV or HSV to sex partners.
- The prevalence of Kaposi's sarcoma has decreased with the widespread availability of effective antiretroviral therapy, yet Kaposi's sarcoma remains the most frequent HIV-associated malignancy. Effective antiretroviral therapy often causes regression of Kaposi's sarcoma lesions without additional therapy.
- The rate of both nosocomial and community-acquired MRSA infections is 6- to 18-fold higher among individuals with HIV than among persons without HIV, and individuals with HIV experience more serious MRSA infections with more frequent recurrences.
- Crusted (or Norwegian) scabies is a severe form of parasitic infection that can be seen in persons with HIV, and it requires multiple doses of oral ivermectin.
- Scaling rashes, including seborrheic dermatitis and psoriasis, are likely due to a dysregulated immune system and often have atypical clinical presentations in persons with HIV.
- Individuals with HIV have a significantly increased risk of developing herpes zoster. All zoster infections warrant therapy with acyclovir, valacyclovir, or famciclovir. The recombinant zoster vaccine is recommended for all adults with HIV.
- Individuals with HIV are more likely to develop HPV-related warts, especially men who have sex with men. Persons with HIV who are aged 9 through 26 years should receive the 9vHPV vaccine. For persons aged 27 through 45 years, the HPV vaccine can be considered based on shared clinical decision-making between the clinician and the client.

Citations

1. Tappero JW, Perkins BA, Wenger JD, Berger TG. Cutaneous manifestations of opportunistic infections in patients infected with human immunodeficiency virus. *Clin Microbiol Rev.* 1995;8:440-50.
[PubMed Abstract] -
2. Maurer TA. Dermatologic manifestations of HIV infection. *Top HIV Med.* 2005 Dec-2006 Jan;13:149-54.
[PubMed Abstract] -
3. Cedeno-Laurent F, Gómez-Flores M, Mendez N, Ancer-Rodríguez J, Bryant JL, Gaspari AA, Trujillo JR. New insights into HIV-1-primary skin disorders. *J Int AIDS Soc.* 2011;14:5.
[PubMed Abstract] -
4. Panel on Opportunistic Infections in Adults and Adolescents with HIV. Guidelines for the prevention and treatment of opportunistic infections in adults and adolescents with HIV: recommendations from the Centers for Disease Control and Prevention, the National Institutes of Health, and the HIV Medicine Association of the Infectious Diseases Society of America. *Bartonellosis.* Updated: November 14, 2023.
[HIV.gov] -
5. Rolain JM, Brouqui P, Koehler JE, Maguina C, Dolan MJ, Raoult D. Recommendations for treatment of human infections caused by *Bartonella* species. *Antimicrob Agents Chemother.* 2004;48:1921-33.
[PubMed Abstract] -
6. Koehler JE, Tappero JW. Bacillary angiomatosis and bacillary peliosis in patients infected with human immunodeficiency virus. *Clin Infect Dis.* 1993;17:612-24.
[PubMed Abstract] -
7. Mosepele M, Mazo D, Cohn J. *Bartonella* infection in immunocompromised hosts: immunology of vascular infection and vasoproliferation. *Clin Dev Immunol.* 2012;2012:612809.
[PubMed Abstract] -
8. Spach DH, Koehler JE. *Bartonella*-associated infections. *Infect Dis Clin North Am.* 1998;12:137-55.
[PubMed Abstract] -
9. Regnery RL, Childs JE, Koehler JE. Infections associated with *Bartonella* species in persons infected with human immunodeficiency virus. *Clin Infect Dis.* 1995;21 Suppl 1:S94-8.
[PubMed Abstract] -
10. Rotunda A, Hirsch RJ, Scheinfeld N, Weinberg JM. Severe cutaneous reactions associated with the use of human immunodeficiency virus medications. *Acta Derm Venereol.* 2003;83:1-9.
[PubMed Abstract] -
11. Luther J, Glesby MJ. Dermatologic adverse effects of antiretroviral therapy: recognition and management. *Am J Clin Dermatol.* 2007;8:221-33.
[PubMed Abstract] -
12. Fearfield LA, Rowe A, Francis N, Bunker CB, Staughton RC. Itchy folliculitis and human immunodeficiency virus infection: clinicopathological and immunological features, pathogenesis and treatment. *Br J Dermatol.* 1999;141:3-11.
[PubMed Abstract] -
13. Afonso JP, Tomimori J, Michalany NS, Nonogaki S, Porro AM. Pruritic papular eruption and eosinophilic folliculitis associated with human immunodeficiency virus (HIV) infection: a histopathological and

immunohistochemical comparative study. *J Am Acad Dermatol.* 2012;67:269-75.

[\[PubMed Abstract\]](#) -

14. Simpson-Dent S, Fearfield LA, Staughton RC. HIV associated eosinophilic folliculitis--differential diagnosis and management. *Sex Transm Infect.* 1999;75:291-3.
[\[PubMed Abstract\]](#) -
15. McQuillan G, Kruszon-Moran D, Flagg EW, Paulose-Ram R. Prevalence of Herpes Simplex Virus Type 1 and Type 2 in Persons Aged 14-49: United States, 2015-2016. *NCHS Data Brief.* 2018;;1-8.
[\[PubMed Abstract\]](#) -
16. Panel on Opportunistic Infections in Adults and Adolescents with HIV. Guidelines for the prevention and treatment of opportunistic infections in adults and adolescents with HIV: recommendations from the Centers for Disease Control and Prevention, the National Institutes of Health, and the HIV Medicine Association of the Infectious Diseases Society of America. Herpes simplex virus. Last updated: May 26, 2020.
[\[HIV.gov\]](#) -
17. Ryder N, Jin F, McNulty AM, Grulich AE, Donovan B. Increasing role of herpes simplex virus type 1 in first-episode anogenital herpes in heterosexual women and younger men who have sex with men, 1992-2006. *Sex Transm Infect.* 2009;85:416-9.
[\[PubMed Abstract\]](#) -
18. Bernstein DI, Bellamy AR, Hook EW 3rd, et al. Epidemiology, clinical presentation, and antibody response to primary infection with herpes simplex virus type 1 and type 2 in young women. *Clin Infect Dis.* 2013;56:344-51.
[\[PubMed Abstract\]](#) -
19. Workowski KA, Bachmann LH, Chan PA, et al. Sexually transmitted infections treatment guidelines, 2021. Diseases characterized by genital, anal, or perianal ulcers: genital herpes. *MMWR Recomm Rep.* 2021;70(No. RR-4):1-187.
[\[2021 STI Treatment Guidelines\]](#) -
20. Tan DH, Raboud JM, Kaul R, Walmsley SL. Antiretroviral therapy is not associated with reduced herpes simplex virus shedding in HIV coinfecting adults: an observational cohort study. *BMJ Open.* 2014;4:e004210.
[\[PubMed Abstract\]](#) -
21. Baeten JM, Strick LB, Lucchetti A, et al. Herpes simplex virus (HSV)-suppressive therapy decreases plasma and genital HIV-1 levels in HSV-2/HIV-1 coinfecting women: a randomized, placebo-controlled, cross-over trial. *J Infect Dis.* 2008;198:1804-8.
[\[PubMed Abstract\]](#) -
22. Moriuchi M, Moriuchi H, Williams R, Straus SE. Herpes simplex virus infection induces replication of human immunodeficiency virus type 1. *Virology.* 2000;278:534-40.
[\[PubMed Abstract\]](#) -
23. Nagot N, Ouedraogo A, Konate I, et al. Roles of clinical and subclinical reactivated herpes simplex virus type 2 infection and human immunodeficiency virus type 1 (HIV-1)-induced immunosuppression on genital and plasma HIV-1 levels. *J Infect Dis.* 2008;198:241-9.
[\[PubMed Abstract\]](#) -
24. Haddow LJ, Dave B, Mindel A, et al. Increase in rates of herpes simplex virus type 1 as a cause of anogenital herpes in western Sydney, Australia, between 1979 and 2003. *Sex Transm Infect.*

2006;82:255-9.

[\[PubMed Abstract\]](#) -

25. Strick LB, Wald A, Celum C. Management of herpes simplex virus type 2 infection in HIV type 1-infected persons. *Clin Infect Dis*. 2006;43:347-56.
[\[PubMed Abstract\]](#) -
26. Tan TY, Zou H, Ong DC, et al. Development and clinical validation of a multiplex real-time PCR assay for herpes simplex and varicella zoster virus. *Diagn Mol Pathol*. 2013;22:245-8.
[\[PubMed Abstract\]](#) -
27. Delany S, Mlaba N, Clayton T, et al. Impact of aciclovir on genital and plasma HIV-1 RNA in HSV-2/HIV-1 co-infected women: a randomized placebo-controlled trial in South Africa. *AIDS*. 2009;23:461-9.
[\[PubMed Abstract\]](#) -
28. Nagot N, Ouédraogo A, Foulongne V, et al. Reduction of HIV-1 RNA levels with therapy to suppress herpes simplex virus. *N Engl J Med*. 2007;356:790-9.
[\[PubMed Abstract\]](#) -
29. Lingappa JR, Baeten JM, Wald A, et al. Daily acyclovir for HIV-1 disease progression in people dually infected with HIV-1 and herpes simplex virus type 2: a randomised placebo-controlled trial. *Lancet*. 2010;375:824-33.
[\[PubMed Abstract\]](#) -
30. Celum C, Wald A, Lingappa JR, et al. Acyclovir and transmission of HIV-1 from persons infected with HIV-1 and HSV-2. *N Engl J Med*. 2010;362:427-39.
[\[PubMed Abstract\]](#) -
31. Mujugira A, Magaret AS, Celum C, et al. Daily acyclovir to decrease herpes simplex virus type 2 (HSV-2) transmission from HSV-2/HIV-1 coinfecting persons: a randomized controlled trial. *J Infect Dis*. 2013;208:1366-74.
[\[PubMed Abstract\]](#) -
32. Yi TJ, Walmsley S, Szadkowski L, et al. A randomized controlled pilot trial of valacyclovir for attenuating inflammation and immune activation in HIV/herpes simplex virus 2-coinfected adults on suppressive antiretroviral therapy. *Clin Infect Dis*. 2013;57:1331-8.
[\[PubMed Abstract\]](#) -
33. Danve-Szatanek C, Aymard M, Thouvenot D, et al. Surveillance network for herpes simplex virus resistance to antiviral drugs: 3-year follow-up. *J Clin Microbiol*. 2004;42:242-9.
[\[PubMed Abstract\]](#) -
34. Reyes M, Shaik NS, Graber JM, et al. Acyclovir-resistant genital herpes among persons attending sexually transmitted disease and human immunodeficiency virus clinics. *Arch Intern Med*. 2003;163:76-80.
[\[PubMed Abstract\]](#) -
35. Erlich KS, Mills J, Chatis P, et al. Acyclovir-resistant herpes simplex virus infections in patients with the acquired immunodeficiency syndrome. *N Engl J Med*. 1989;320:293-6.
[\[PubMed Abstract\]](#) -
36. Gilbert C, Bestman-Smith J, Boivin G. Resistance of herpesviruses to antiviral drugs: clinical impacts and molecular mechanisms. *Drug Resist Updat*. 2002;5:88-114.

[\[PubMed Abstract\]](#) -

37. Safrin S, Assaykeen T, Follansbee S, Mills J. Foscarnet therapy for acyclovir-resistant mucocutaneous herpes simplex virus infection in 26 AIDS patients: preliminary data. *J Infect Dis.* 1990;161:1078-84. [\[PubMed Abstract\]](#) -
38. Balfour HH Jr. Antiviral Drugs. *N Engl J Med.* 1999;340:1255-68. [\[PubMed Abstract\]](#) -
39. Safrin S, Crumpacker C, Chatis P, et al. A controlled trial comparing foscarnet with vidarabine for acyclovir-resistant mucocutaneous herpes simplex in the acquired immunodeficiency syndrome. The AIDS Clinical Trials Group. *N Engl J Med.* 1991;325:551-5. [\[PubMed Abstract\]](#) -
40. Panel on Opportunistic Infections in Adults and Adolescents with HIV. Guidelines for the prevention and treatment of opportunistic infections in adults and adolescents with HIV: recommendations from the Centers for Disease Control and Prevention, the National Institutes of Health, and the HIV Medicine Association of the Infectious Diseases Society of America. Human herpesvirus-8. May 29, 2018. [\[HIV.gov\]](#) -
41. Bower M, Weir J, Francis N, et al. The effect of HAART in 254 consecutive patients with AIDS-related Kaposi's sarcoma. *AIDS.* 2009;23:1701-6. [\[PubMed Abstract\]](#) -
42. Shiels MS, Pfeiffer RM, Gail MH, et al. Cancer burden in the HIV-infected population in the United States. *J Natl Cancer Inst.* 2011;103:753-62. [\[PubMed Abstract\]](#) -
43. Silverberg MJ, Neuhaus J, Bower M, et al. Risk of cancers during interrupted antiretroviral therapy in the SMART study. *AIDS.* 2007;21:1957-63. [\[PubMed Abstract\]](#) -
44. Di Lorenzo G, Konstantinopoulos PA, Pantanowitz L, Di Trollo R, De Placido S, Dezube BJ. Management of AIDS-related Kaposi's sarcoma. *Lancet Oncol.* 2007;8:167-76. [\[PubMed Abstract\]](#) -
45. Sullivan SG, Hirsch HH, Franceschi S, et al. Kaposi sarcoma herpes virus antibody response and viremia following highly active antiretroviral therapy in the Swiss HIV Cohort study. *AIDS.* 2010;24:2245-52. [\[PubMed Abstract\]](#) -
46. Gbabe OF, Okwundu CI, Dedicoat M, Freeman EE. Treatment of severe or progressive Kaposi's sarcoma in HIV-infected adults. *Cochrane Database Syst Rev.* 2014;8:CD003256. [\[PubMed Abstract\]](#) -
47. Kotpal R, Krishna PS, Bhalla P, Dewan R, Kaur R. Incidence and Risk Factors of Nasal Carriage of *Staphylococcus aureus* in HIV-Infected Individuals in Comparison to HIV-Uninfected Individuals: A Case-Control Study. *J Int Assoc Provid AIDS Care.* 2014;pii: 2325957414554005. [\[PubMed Abstract\]](#) -
48. Skiest D, Brown K, Hester J, Moore T, Crosby C, Mussa HR, Hoffman-Roberts H, Cooper T. Community-onset methicillin-resistant *Staphylococcus aureus* in an urban HIV clinic. *HIV Med.* 2006;7:361-8. [\[PubMed Abstract\]](#) -

49. Popovich KJ, Weinstein RA, Aroutcheva A, Rice T, Hota B. Community-associated methicillin-resistant *Staphylococcus aureus* and HIV: intersecting epidemics. *Clin Infect Dis*. 2010;50:979-87.
[\[PubMed Abstract\]](#) -
50. Crum-Cianflone NF, Burgi AA, Hale BR. Increasing rates of community-acquired methicillin-resistant *Staphylococcus aureus* infections among HIV-infected persons. *Int J STD AIDS*. 2007;18:521-6.
[\[PubMed Abstract\]](#) -
51. Shadyab AH, Crum-Cianflone NF. Methicillin-resistant *Staphylococcus aureus* (MRSA) infections among HIV-infected persons in the era of highly active antiretroviral therapy: a review of the literature. *HIV Med*. 2012;13:319-32.
[\[PubMed Abstract\]](#) -
52. Crum-Cianflone NF, Shadyab AH, Weintrob A, et al. Association of methicillin-resistant *Staphylococcus aureus* (MRSA) colonization with high-risk sexual behaviors in persons infected with human immunodeficiency virus (HIV). *Medicine (Baltimore)*. 2011;90:379-89.
[\[PubMed Abstract\]](#) -
53. Liu C, Bayer A, Cosgrove SE, et al. Clinical practice guidelines by the infectious diseases society of america for the treatment of methicillin-resistant *Staphylococcus aureus* infections in adults and children. *Clin Infect Dis*. 2011;52:e18-55.
[\[PubMed Abstract\]](#) -
54. Strauss RM, Doyle EL, Mohsen AH, Green ST. Successful treatment of molluscum contagiosum with topical imiquimod in a severely immunocompromised HIV-positive patient. *Int J STD AIDS*. 2001;12:264-6.
[\[PubMed Abstract\]](#) -
55. Meza-Romero R, Navarrete-Dechent C, Downey C. Molluscum contagiosum: an update and review of new perspectives in etiology, diagnosis, and treatment. *Clin Cosmet Investig Dermatol*. 2019;12:373-81.
[\[PubMed Abstract\]](#) -
56. Cotell SL, Roholt NS. Images in clinical medicine. Molluscum contagiosum in a patient with the acquired immunodeficiency syndrome. *N Engl J Med*. 1998;338:888.
[\[PubMed Abstract\]](#) -
57. Chen X, Anstey AV, Bugert JJ. Molluscum contagiosum virus infection. *Lancet Infect Dis*. 2013;13:877-88.
[\[PubMed Abstract\]](#) -
58. Bachmeyer C, Moguelet P, Baud F, Lescure FX. Efflorescence of facial molluscum contagiosum as a manifestation of immune reconstitution inflammatory syndrome in a patient with AIDS. *Eur J Dermatol*. 2009;19:257-8.
[\[PubMed Abstract\]](#) -
59. Calista D, Boschini A, Landi G. Resolution of disseminated molluscum contagiosum with Highly Active Anti-Retroviral Therapy (HAART) in patients with AIDS. *Eur J Dermatol*. 1999;9:211-3.
[\[PubMed Abstract\]](#) -
60. Hicks CB, Myers SA, Giner J. Resolution of intractable molluscum contagiosum in a human immunodeficiency virus-infected patient after institution of antiretroviral therapy with ritonavir. *Clin Infect Dis*. 1997;24:1023-5.
[\[PubMed Abstract\]](#) -

61. Sen S, Goswami BK, Karjyi N, Bhaumik P. Disfiguring molluscum contagiosum in a HIV-positive patient responding to antiretroviral therapy. *Indian J Dermatol.* 2009;54:180-2.
[\[PubMed Abstract\]](#) -
62. Menon K, Van Voorhees AS, Bebo BF Jr, et al. Psoriasis in patients with HIV infection: from the medical board of the National Psoriasis Foundation. *J Am Acad Dermatol.* 2010;62:291-9.
[\[PubMed Abstract\]](#) -
63. Morar N, Willis-Owen SA, Maurer T, Bunker CB. HIV-associated psoriasis: pathogenesis, clinical features, and management. *Lancet Infect Dis.* 2010;10:470-8.
[\[PubMed Abstract\]](#) -
64. Mallon E. Retroviruses and psoriasis. *Curr Opin Infect Dis.* 2000;13:103-107.
[\[PubMed Abstract\]](#) -
65. Corbett EL, Crossley I, Holton J, Levell N, Miller R, De Cock KM. Crusted ("Norwegian") scabies in a specialist HIV unit: successful use of ivermectin and failure to prevent nosocomial transmission. *Genitourin Med.* 1996;72:115-7.
[\[PubMed Abstract\]](#) -
66. de Vries HJ. Skin as an indicator for sexually transmitted infections. *Clin Dermatol.* 2014;32:196-208.
[\[PubMed Abstract\]](#) -
67. Orkin M. Scabies in AIDS. *Semin Dermatol.* 1993;12:9-14.
[\[PubMed Abstract\]](#) -
68. Fernández-Sánchez M, Saeb-Lima M, Alvarado-de la Barrera C, Reyes-Terán G. Crusted scabies-associated immune reconstitution inflammatory syndrome. *BMC Infect Dis.* 2012;12:323.
[\[PubMed Abstract\]](#) -
69. Chosidow O. Clinical practices. Scabies. *N Engl J Med.* 2006;354:1718-27.
[\[PubMed Abstract\]](#) -
70. Heukelbach J, Feldmeier H. Scabies. *Lancet.* 2006;367:1767-74.
[\[PubMed Abstract\]](#) -
71. Strong M, Johnstone P. Interventions for treating scabies. *Cochrane Database Syst Rev.* 2007;:CD000320.
[\[PubMed Abstract\]](#) -
72. Workowski KA, Bachmann LH, Chan PA, et al. Sexually transmitted infections treatment guidelines, 2021. Ectoparasitic infections. *MMWR Recomm Rep.* 2021;70(No. RR-4):1-187.
[\[2021 STI Treatment Guidelines\]](#) -
73. Meinking TL, Taplin D, Hermida JL, Pardo R, Kerdel FA. The treatment of scabies with ivermectin. *N Engl J Med.* 1995;333:26-30.
[\[PubMed Abstract\]](#) -
74. Gupta AK, Bluhm R. Seborrheic dermatitis. *J Eur Acad Dermatol Venereol.* 2004;18:13-26.
[\[PubMed Abstract\]](#) -
75. Naldi L, Rebora A. Clinical practice. Seborrheic dermatitis. *N Engl J Med.* 2009;360:387-96.
[\[PubMed Abstract\]](#) -

76. Dunic I, Vesic S, Jevtovic DJ. Oral candidiasis and seborrheic dermatitis in HIV-infected patients on highly active antiretroviral therapy. *HIV Med.* 2004;5:50-4.
[\[PubMed Abstract\]](#) -
77. Panel on Opportunistic Infections in Adults and Adolescents with HIV. Guidelines for the prevention and treatment of opportunistic infections in adults and adolescents with HIV: recommendations from the Centers for Disease Control and Prevention, the National Institutes of Health, and the HIV Medicine Association of the Infectious Diseases Society of America. Varicella-zoster virus disease. Last updated: September 7, 2022.
[\[HIV.gov\]](#) -
78. Buchbinder SP, Katz MH, Hessel NA, Liu JY, O'Malley PM, Underwood R, Holmberg SD. Herpes zoster and human immunodeficiency virus infection. *J Infect Dis.* 1992;166:1153-6.
[\[PubMed Abstract\]](#) -
79. Donahue JG, Choo PW, Manson JE, Platt R. The incidence of herpes zoster. *Arch Intern Med.* 1995;155:1605-9.
[\[PubMed Abstract\]](#) -
80. Domingo P, Torres OH, Ris J, Vazquez G. Herpes zoster as an immune reconstitution disease after initiation of combination antiretroviral therapy in patients with human immunodeficiency virus type-1 infection. *Am J Med.* 2001;110:605-9.
[\[PubMed Abstract\]](#) -
81. Liu C, Wang C, Glesby MJ, et al. Effects of highly active antiretroviral therapy and its adherence on herpes zoster incidence: a longitudinal cohort study. *AIDS Res Ther.* 2013;10:34.
[\[PubMed Abstract\]](#) -
82. Forbes HJ, Bhaskaran K, Thomas SL, et al. Quantification of risk factors for postherpetic neuralgia in herpes zoster patients: A cohort study. *Neurology.* 2016;87:94-102.
[\[PubMed Abstract\]](#) -
83. Balfour HH Jr, Bean B, Laskin OL, et al. Acyclovir halts progression of herpes zoster in immunocompromised patients. *N Engl J Med.* 1983;308:1448-53.
[\[PubMed Abstract\]](#) -
84. Breton G, Fillet AM, Katlama C, Bricaire F, Caumes E. Acyclovir-resistant herpes zoster in human immunodeficiency virus-infected patients: results of foscarnet therapy. *Clin Infect Dis.* 1998;27:1525-7.
[\[PubMed Abstract\]](#) -
85. Centers for Disease Control and Prevention (CDC). Updated recommendations for use of VariZIG--United States, 2013. *MMWR Morb Mortal Wkly Rep.* 2013;62:574-6.
[\[PubMed Abstract\]](#) -
86. Weinstock DM, Boeckh M, Sepkowitz KA. Postexposure prophylaxis against varicella zoster virus infection among hematopoietic stem cell transplant recipients. *Biol Blood Marrow Transplant.* 2006;12:1096-7.
[\[PubMed Abstract\]](#) -
87. Panel on Opportunistic Infections in Adults and Adolescents with HIV. Guidelines for the prevention and treatment of opportunistic infections in adults and adolescents with HIV: recommendations from the Centers for Disease Control and Prevention, the National Institutes of Health, and the HIV Medicine

Association of the Infectious Diseases Society of America. Human papillomavirus disease. July 9, 2024. [[HIV.gov](#)] -

88. Dolev JC, Maurer T, Springer G, et al. Incidence and risk factors for verrucae in women. AIDS. 2008;22:1213-9. [[PubMed Abstract](#)] -
89. Workowski KA, Bachmann LH, Chan PA, et al. Sexually transmitted infections treatment guidelines, 2021. Human papillomavirus (HPV) infection: anogenital warts. MMWR Recomm Rep. 2021;70(No. RR-4):1-187. [[2021 STI Treatment Guidelines](#)] -
90. Meites E, Szilagyi PG, Chesson HW, Unger ER, Romero JR, Markowitz LE. Human Papillomavirus Vaccination for Adults: Updated Recommendations of the Advisory Committee on Immunization Practices. MMWR Morb Mortal Wkly Rep. 2019;68:698-702. [[PubMed Abstract](#)] -
91. Wilkin TJ, Chen H, Cespedes MS, et al. A Randomized, Placebo-Controlled Trial of the Quadrivalent Human Papillomavirus Vaccine in Human Immunodeficiency Virus-Infected Adults Aged 27 Years or Older: AIDS Clinical Trials Group Protocol A5298. Clin Infect Dis. 2018;67:1339-46. [[PubMed Abstract](#)] -

References

- Advisory Committee on Immunization Practices (ACIP). Recommended Adult Immunization Schedule by Medical Condition and Other Indications, United States, 2025. [[ACIP](#)] -
- Advisory Committee on Immunization Practices (ACIP). Recommended Immunization Schedule for Ages 19 Years or Older, United States, 2025. [[ACIP](#)] -
- Alpalhão M, Borges-Costa J, Filipe P. Psoriasis in HIV infection: an update. Int J STD AIDS. 2019;30:596-604. [[PubMed Abstract](#)] -
- Baxter KF, Hight AS. Topical cidofovir and cryotherapy—combination treatment for recalcitrant molluscum contagiosum in a patient with HIV infection. J Eur Acad Dermatol Venereol. 2004;18:230-1. [[PubMed Abstract](#)] -
- Bendle M, Pealing J, Papanastasopoulos P, Bower M. Liposomal anthracycline chemotherapy and the risk of second malignancies in patients with Kaposi's sarcoma (KS). Cancer Chemother Pharmacol. 2014;74:611-5. [[PubMed Abstract](#)] -
- Benson CA, Andersen JW, Macatangay BJC, et al. Safety and Immunogenicity of Zoster Vaccine Live in Human Immunodeficiency Virus-Infected Adults With CD4+ Cell Counts >200 Cells/mL Virologically Suppressed on Antiretroviral Therapy. Clin Infect Dis. 2018;67:1712-9. [[PubMed Abstract](#)] -
- Berger TG, Heon V, King C, Schulze K, Conant MA. Itraconazole therapy for human immunodeficiency virus-associated eosinophilic folliculitis. Arch Dermatol. 1995;131:358-60. [[PubMed Abstract](#)] -

- Bridges CB, Coyne-Beasley T. Advisory Committee on Immunization Practices recommended immunization schedule for adults aged 19 years or older - United States, 2014. MMWR Morb Mortal Wkly Rep. 2014;63:110-2.
[MMWR] -
- Centers for Disease Control and Prevention (CDC). Discordant results from reverse sequence syphilis screening--five laboratories, United States, 2006-2010. MMWR Morb Mortal Wkly Rep. 2011;60:133-7.
[MMWR] -
- Dolev JC, Maurer T, Springer G, et al. Incidence and risk factors for verrucae in women. AIDS. 2008;22:1213-9.
[PubMed Abstract] -
- Dooling KL, Guo A, Patel M, et al. Recommendations of the Advisory Committee on Immunization Practices for Use of Herpes Zoster Vaccines. MMWR Morb Mortal Wkly Rep. 2018;67:103-108.
[PubMed Abstract] -
- Dunic I, Vesic S, Jevtovic DJ. Oral candidiasis and seborrheic dermatitis in HIV-infected patients on highly active antiretroviral therapy. HIV Med. 2004;5:50-4.
[PubMed Abstract] -
- Freeman EE, Weiss HA, Glynn JR, Cross PL, Whitworth JA, Hayes RJ. Herpes simplex virus 2 infection increases HIV acquisition in men and women: systematic review and meta-analysis of longitudinal studies. AIDS. 2006;20:73-83.
[PubMed Abstract] -
- Hemmige V, Arias CA, Pasalar S, Giordano TP. Skin and Soft Tissue Infection in People Living With Human Immunodeficiency Virus in a Large, Urban, Public Healthcare System in Houston, Texas, 2009-2014. Clin Infect Dis. 2020;70:1985-92.
[PubMed Abstract] -
- Kim DK, Hunter P. Recommended Adult Immunization Schedule, United States, 2019. Ann Intern Med. 2019;170:182-92.
[PubMed Abstract] -
- Levin MJ, Bacon TH, Leary JJ. Resistance of herpes simplex virus infections to nucleoside analogues in HIV-infected patients. Clin Infect Dis. 2004;39 Suppl 5:S248-57.
[PubMed Abstract] -
- Maguina C, Garcia PJ, Gotuzzo E, Cordero L, Spach DH. Bartonellosis (Carrión's disease) in the modern era. Clin Infect Dis. 2001;33:772-9.
[PubMed Abstract] -
- Marra CM, Maxwell CL, Smith SL, et al. Cerebrospinal fluid abnormalities in patients with syphilis: association with clinical and laboratory features. J Infect Dis. 2004;189:369-76.
[PubMed Abstract] -
- Mullane KM, Winston DJ, Wertheim MS, et al. Safety and immunogenicity of heat-treated zoster vaccine (ZVHT) in immunocompromised adults. J Infect Dis. 2013;208:1375-85.
[PubMed Abstract] -
- Piret J, Boivin G. Resistance of herpes simplex viruses to nucleoside analogues: mechanisms, prevalence, and management. Antimicrob Agents Chemother. 2011;55:459-72.

[\[PubMed Abstract\]](#) -

- Van Wagoner N, Geisler WM, Bachmann LH, Hook EW. The effect of valacyclovir on HIV and HSV-2 in HIV-infected persons on antiretroviral therapy with previously unrecognised HSV-2. *Int J STD AIDS*. 2015;26:574-81.
[\[PubMed Abstract\]](#) -
- Zervou FN, Zacharioudakis IM, Ziakas PD, Rich JD, Mylonakis E. Prevalence of and risk factors for methicillin-resistant *Staphylococcus aureus* colonization in HIV infection: a meta-analysis. *Clin Infect Dis*. 2014;59:1302-11.
[\[PubMed Abstract\]](#) -

Figures

Figure 1 Nodular Bacillary Angiomatosis Lesion in Right Antecubital Fossa

Photograph credit: David H. Spach, MD

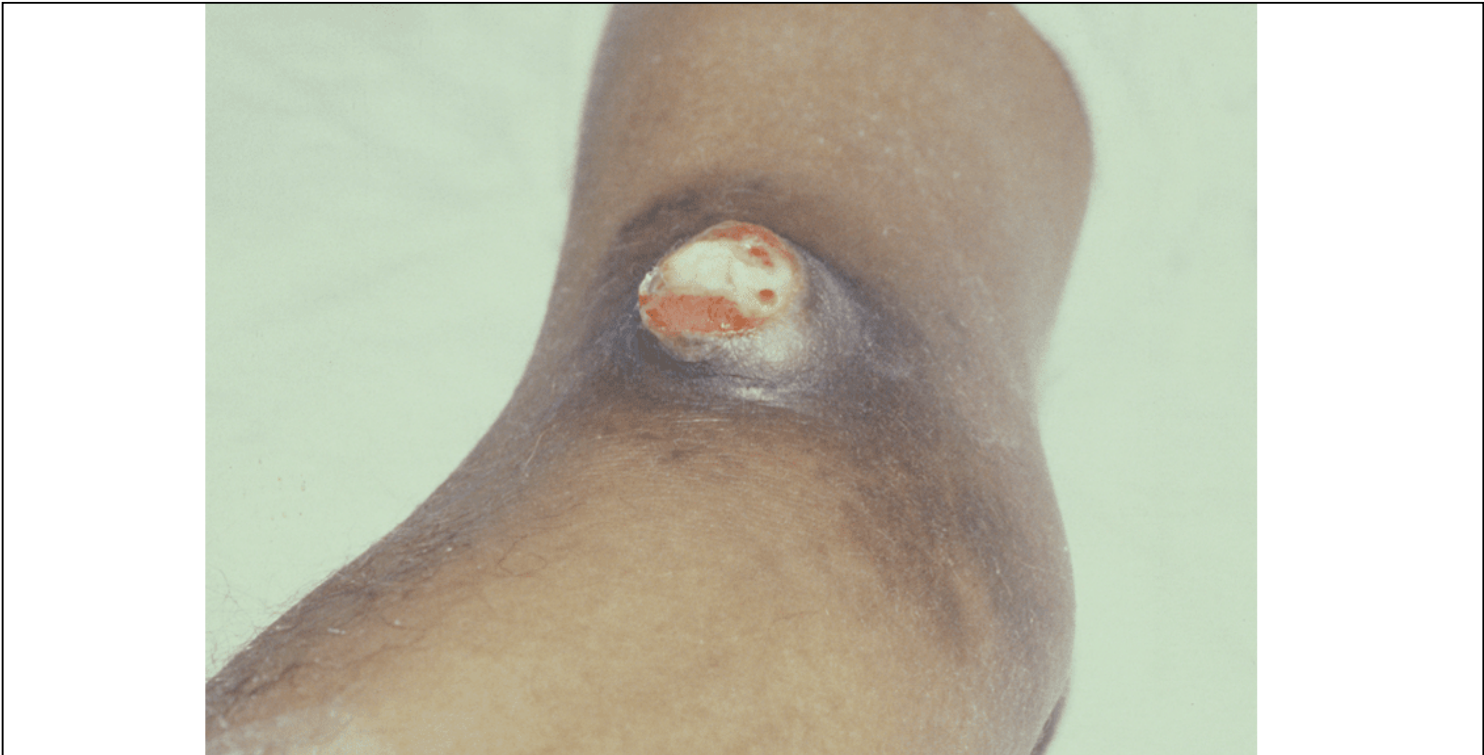

Figure 2 Cutaneous Drug Eruption Caused by Efavirenz

Photograph credit: David H. Spach, MD

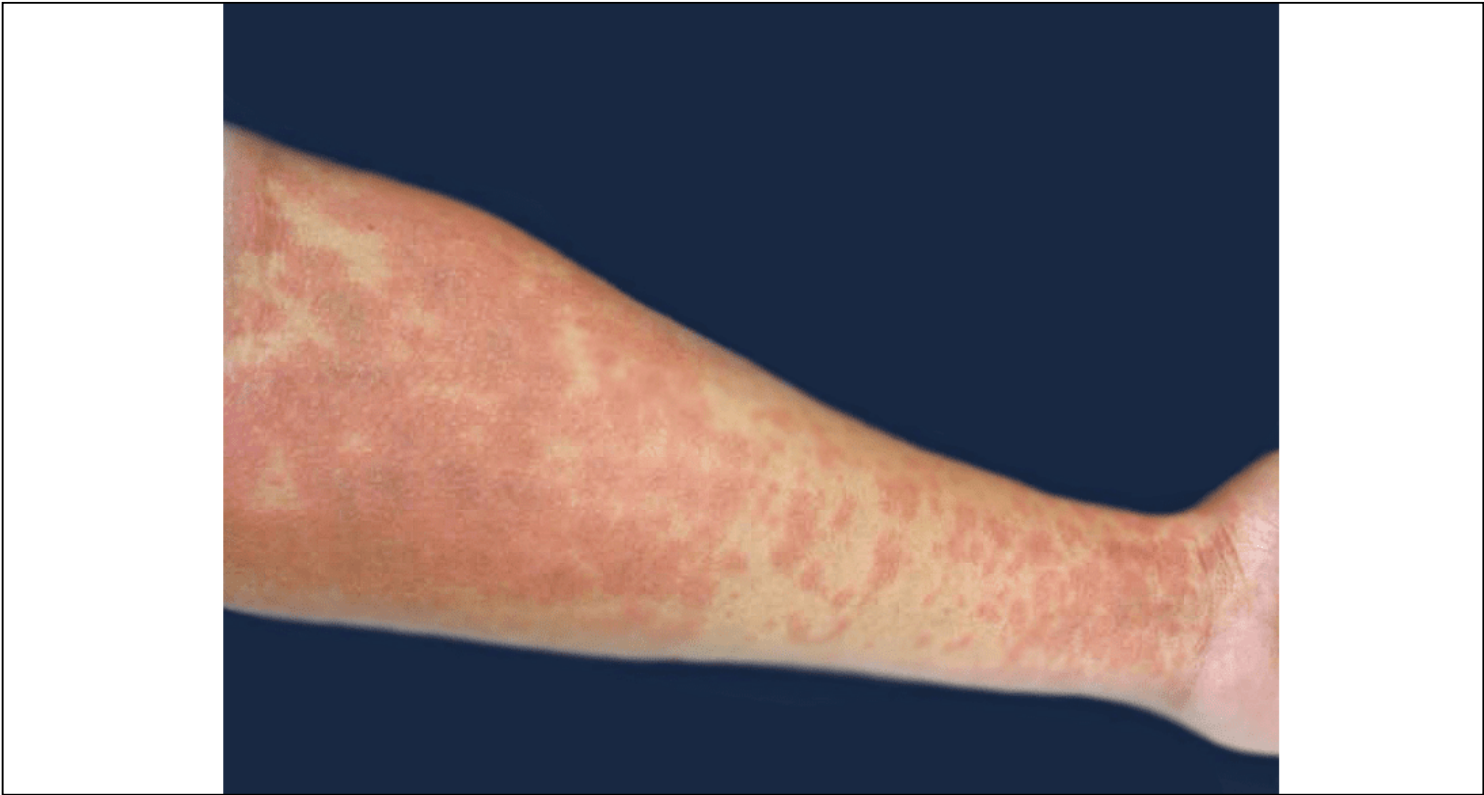

Figure 3 (Image Series) - Herpes Simplex Cutaneous Infections (Image Series) - Figure 3 (Image Series) - Herpes Simplex Cutaneous Infections
Image 3A: Chronic Ulcerative Herpes Simplex Virus Lesions on Face

Photograph credit: David H. Spach, MD

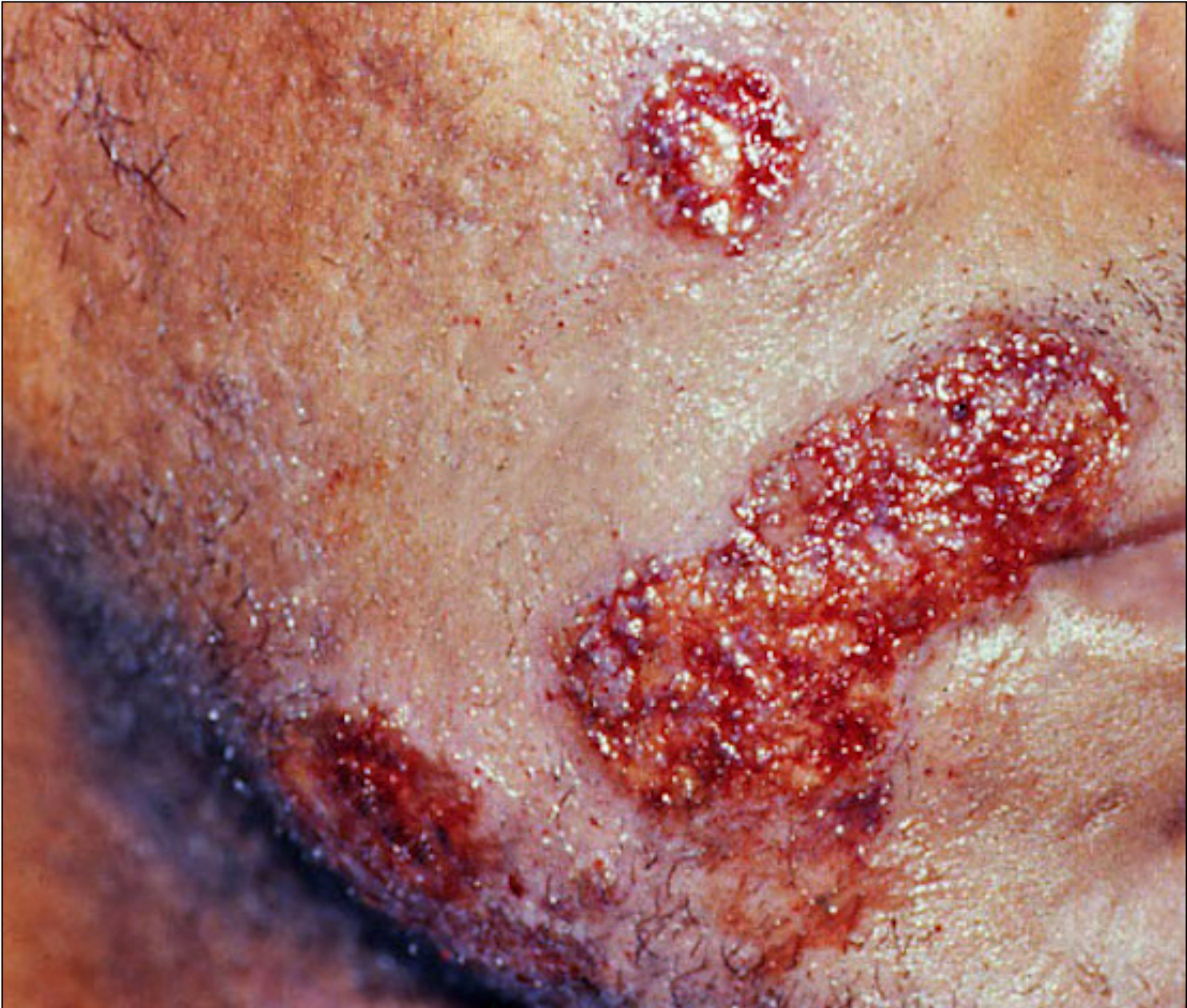

Figure 3 (Image Series) - Herpes Simplex Cutaneous Infections
Image 3B: Chronic Ulcerative Herpes Simplex Virus Infection on Right Ear

Photograph credit: David H. Spach, MD

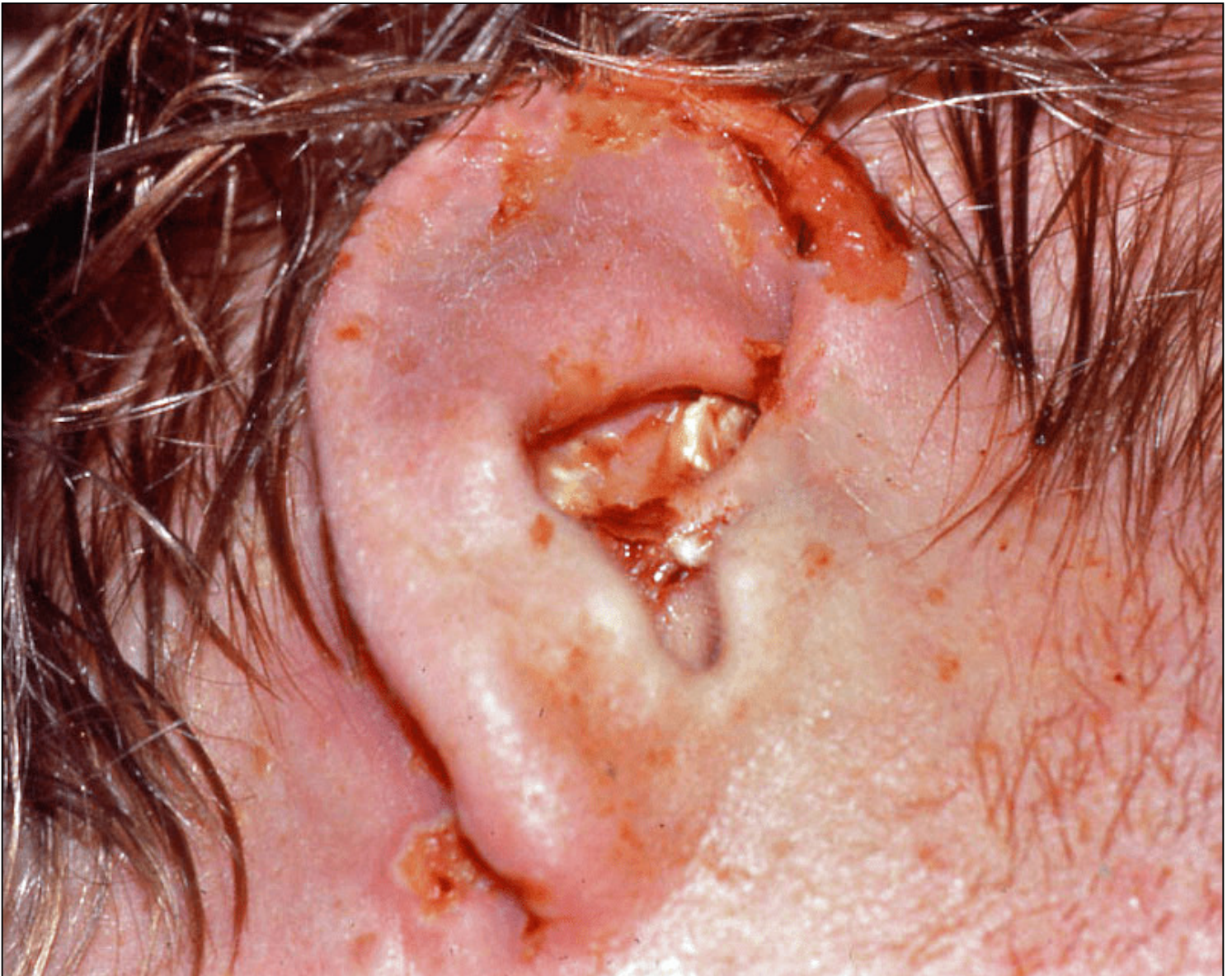

Figure 3 (Image Series) - Herpes Simplex Cutaneous Infections
Image 3C: Multiple Herpes Simplex Virus Infection Lesions on Scrotum

Photograph credit: David H. Spach, MD

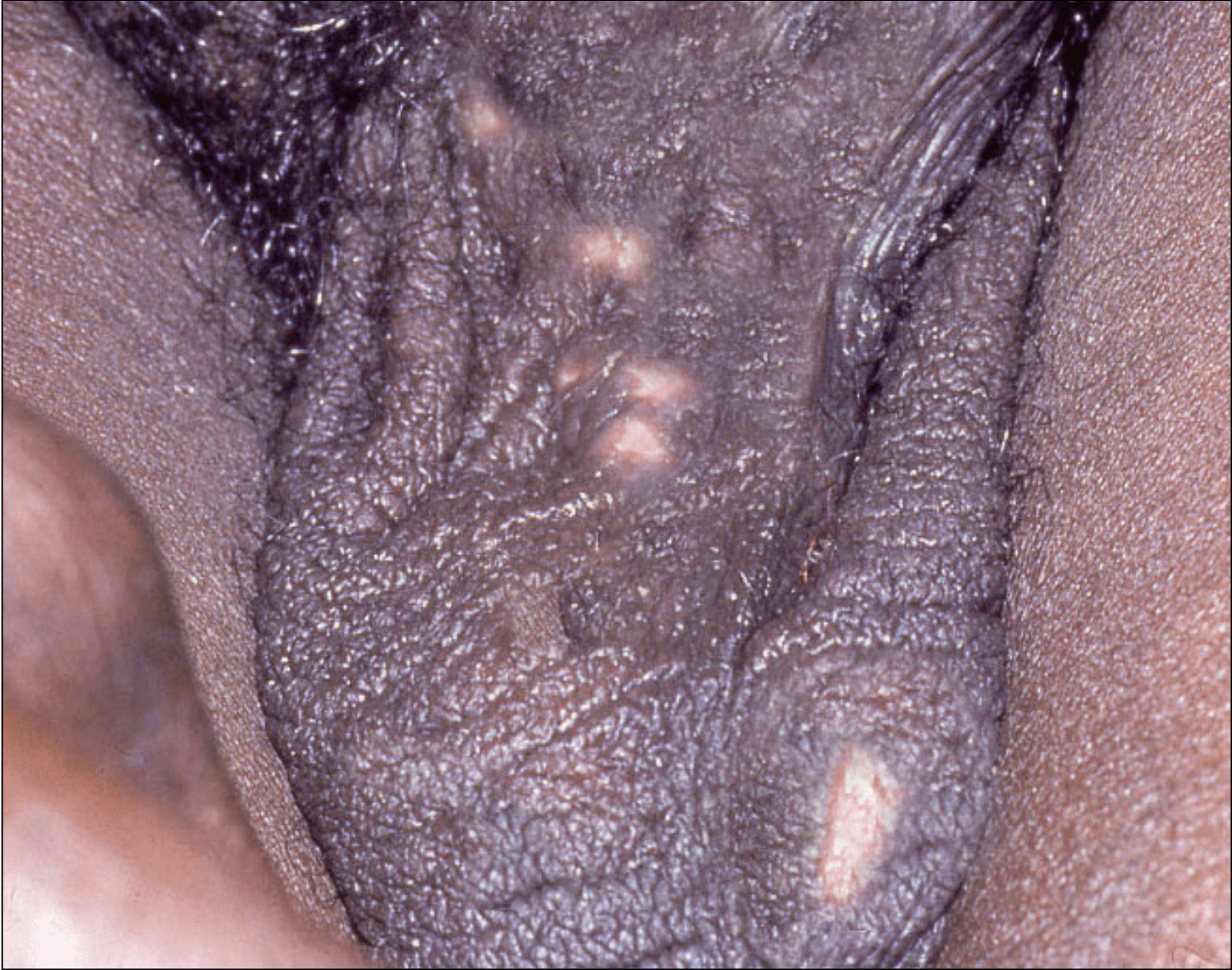

Figure 4 Destructive Acyclovir-Resistant Herpes Simplex Virus Infection on Face

Photograph credit: David H. Spach, MD

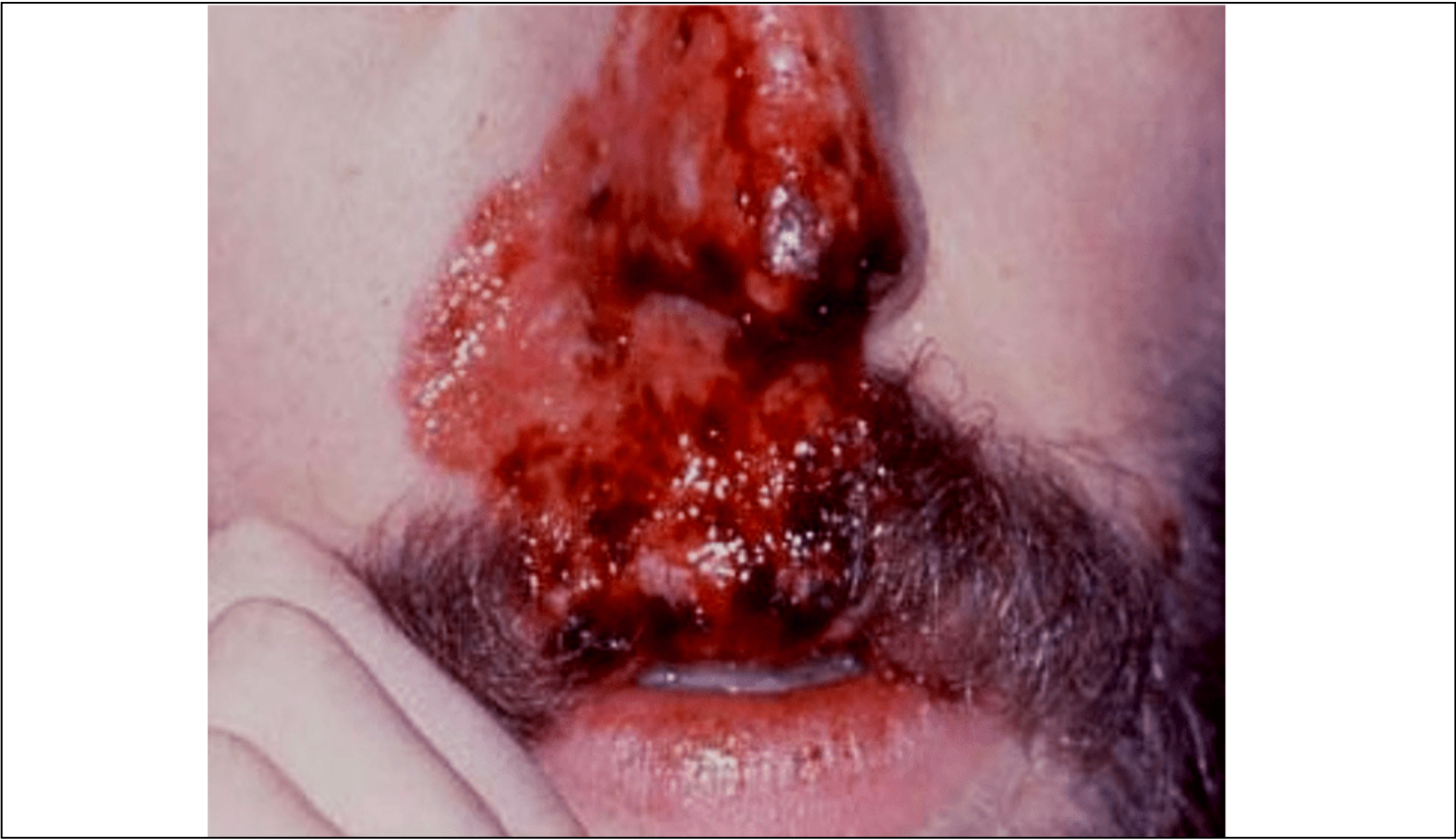

Figure 5 (Image Series) - Mechanism for Acyclovir-Resistant Herpes Simplex Virus (Image Series)
- Figure 5 (Image Series) - Mechanism for Acyclovir-Resistant Herpes Simplex Virus
Image 5A: Acyclovir: Mechanism of Action

The activation of acyclovir requires three phosphorylation steps. Note the first phosphorylation occurs via the HSV thymidine kinase enzyme.
Abbreviations: ACV = acyclovir; P = phosphate; HSV TK = herpes simplex viru thymidine kinase

Illustration by David H. Spach, MD

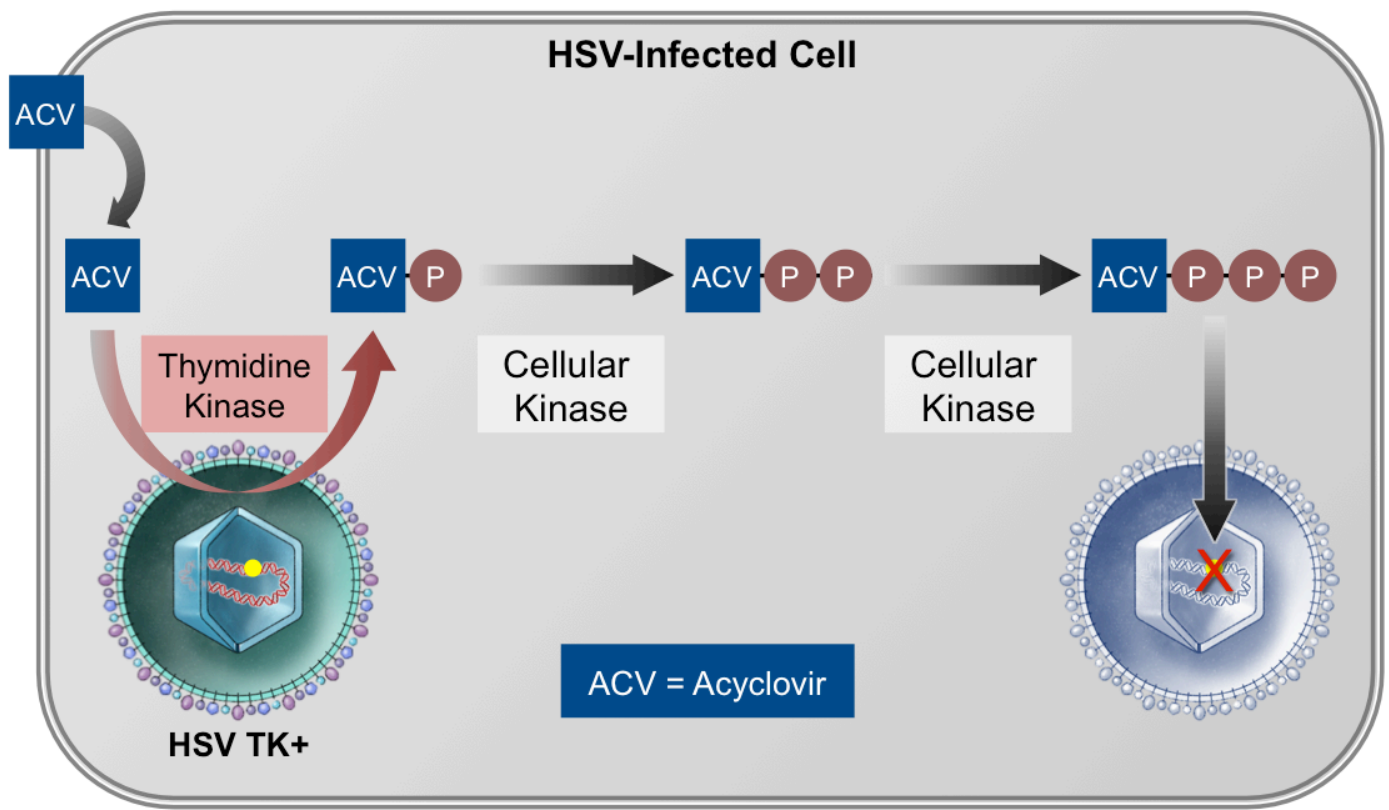


Figure 5 (Image Series) - Mechanism for Acyclovir-Resistant Herpes Simplex Virus
Image 5B: Thymidine Kinase-Negative, Acyclovir-Resistant Herpes simplex Virus

With absent production of thymidine kinase the acyclovir phosphorylation cascade does not start and the drug is inactive.

Abbreviations: ACV = acyclovir; P = phosphate; HSV TK = herpes simplex viru thymidine kinase

Illustration by David H. Spach, MD

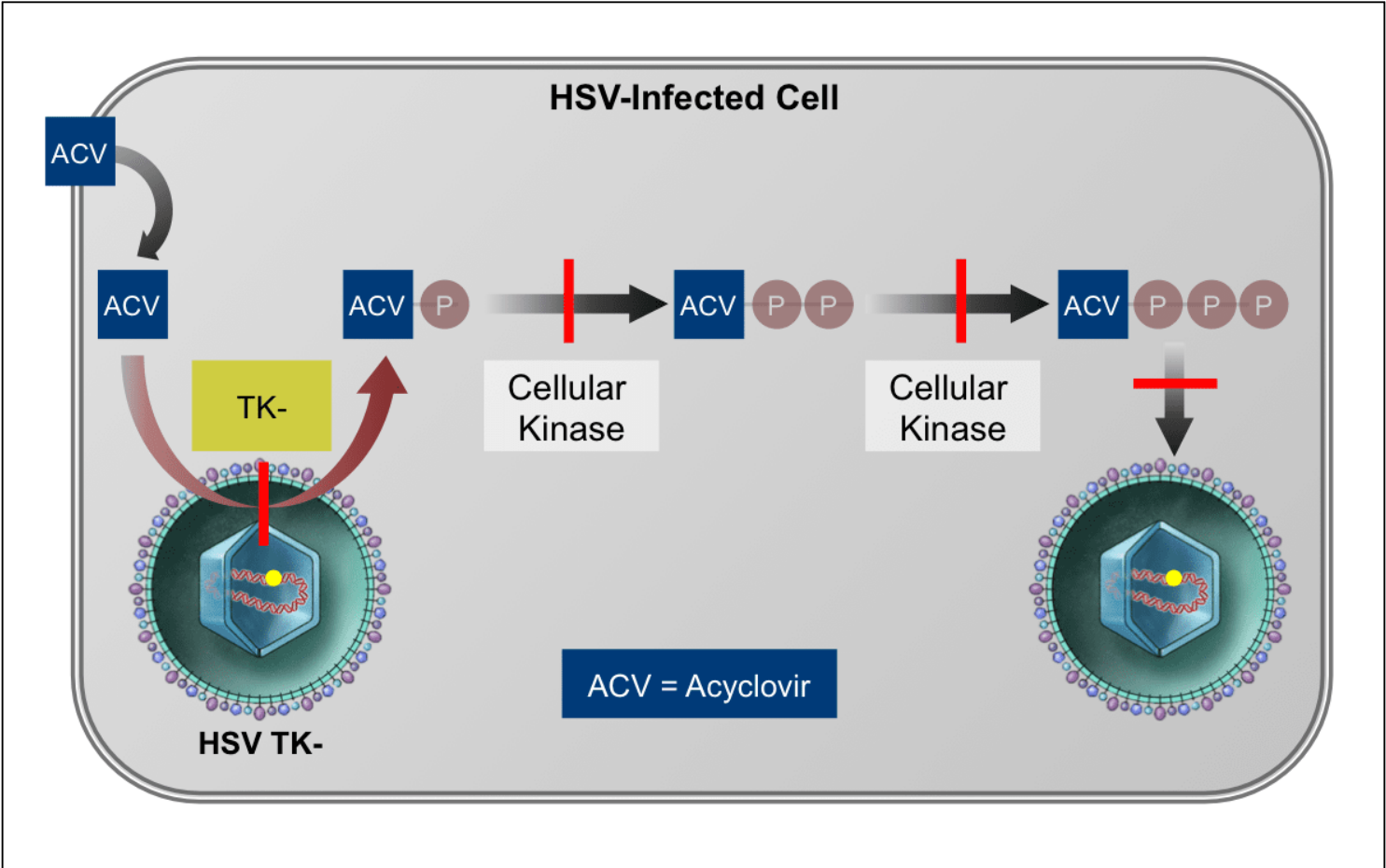


Figure 6 (Image Series) - Kaposi's Sarcoma—Cutaneous Manifestations (Image Series) - Figure 6 (Image Series) - Kaposi's Sarcoma—Cutaneous Manifestations
Image 6A: Isolated Solitary Kaposi's Sarcoma Lesion on Arm

Photograph credit: David H. Spach, MD

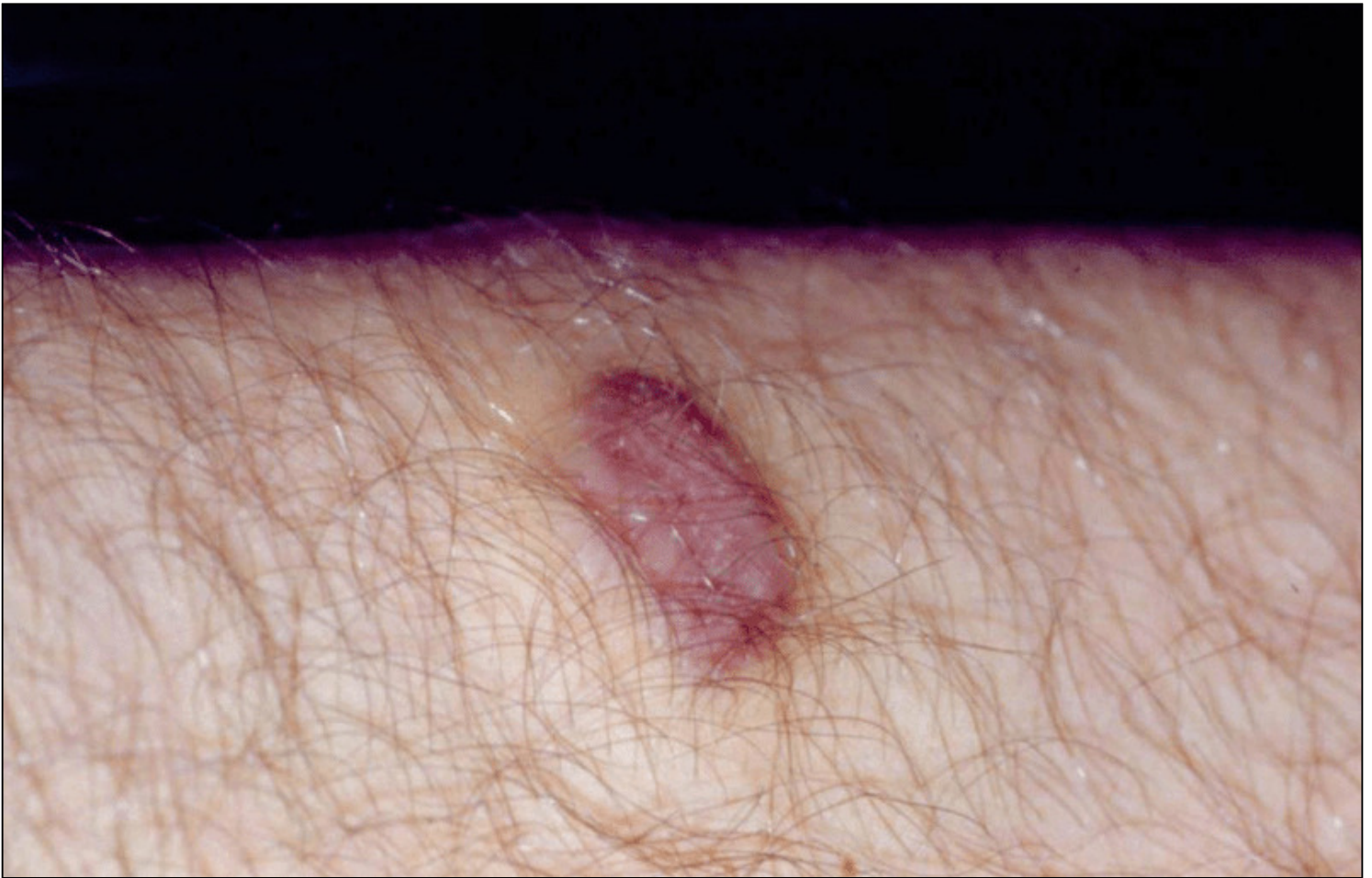

Figure 6 (Image Series) - Kaposi's Sarcoma—Cutaneous Manifestations
Image 6B: Kaposi's Sarcoma Lesions on Nose

Photograph credit: David H. Spach, MD

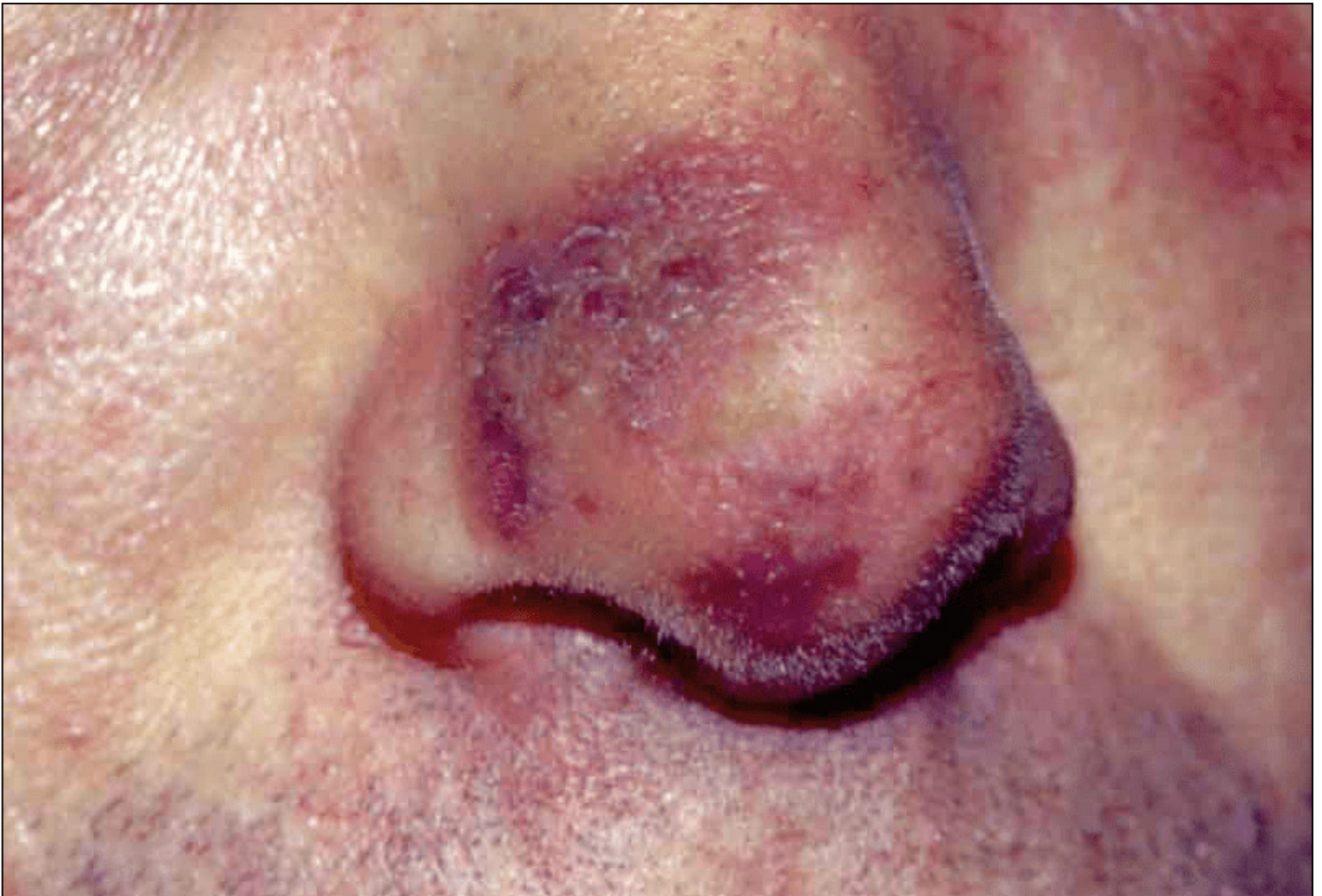

Figure 6 (Image Series) - Kaposi's Sarcoma—Cutaneous Manifestations
Image 6C: Multiple Kaposi's Sarcoma Lesions on Chest and Arms

Photograph credit: David H. Spach, MD

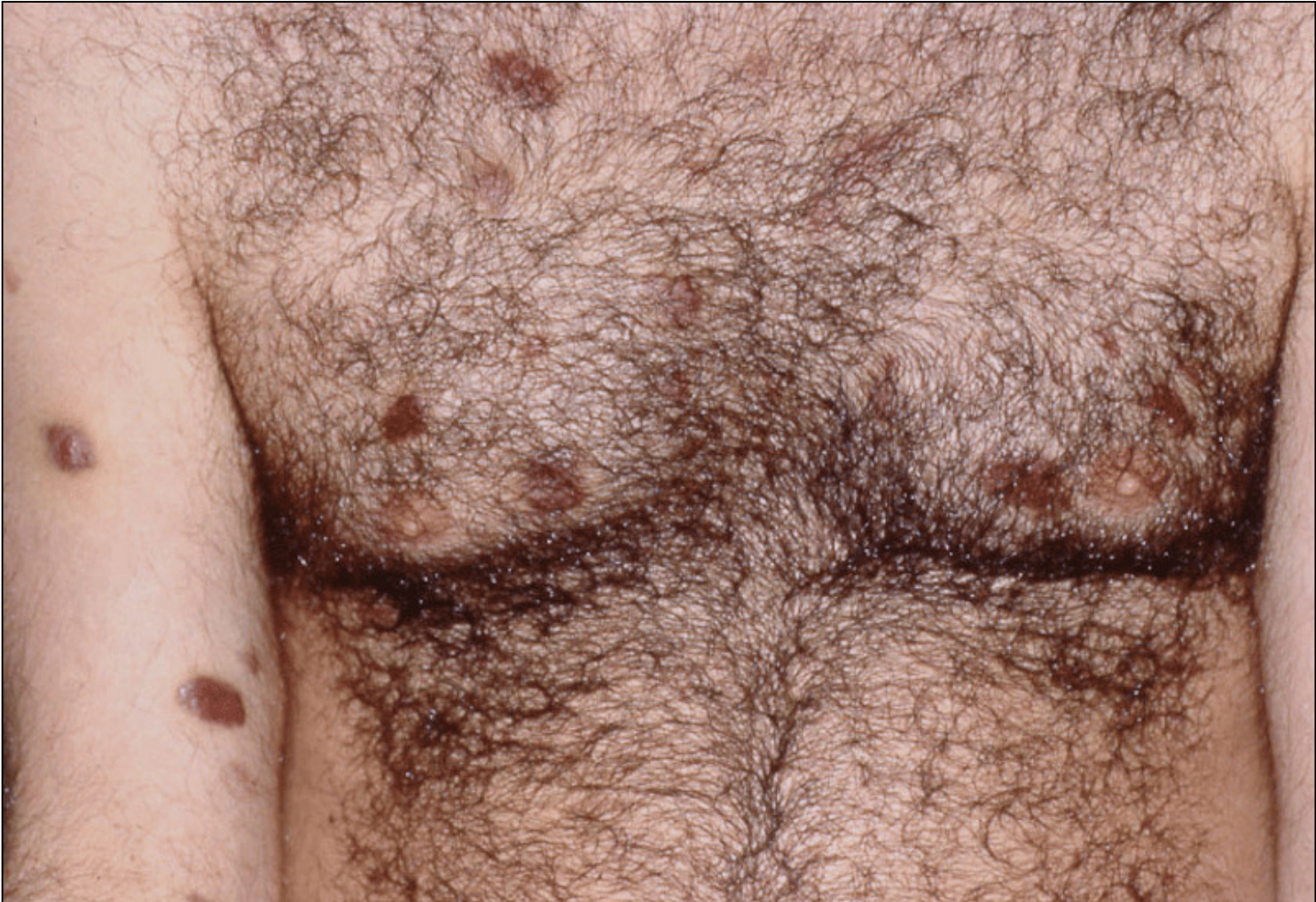

Figure 6 (Image Series) - Kaposi's Sarcoma—Cutaneous Manifestations
Image 6D: Kaposi's Sarcoma on Right Second Toe

Photograph credit: David H. Spach, MD

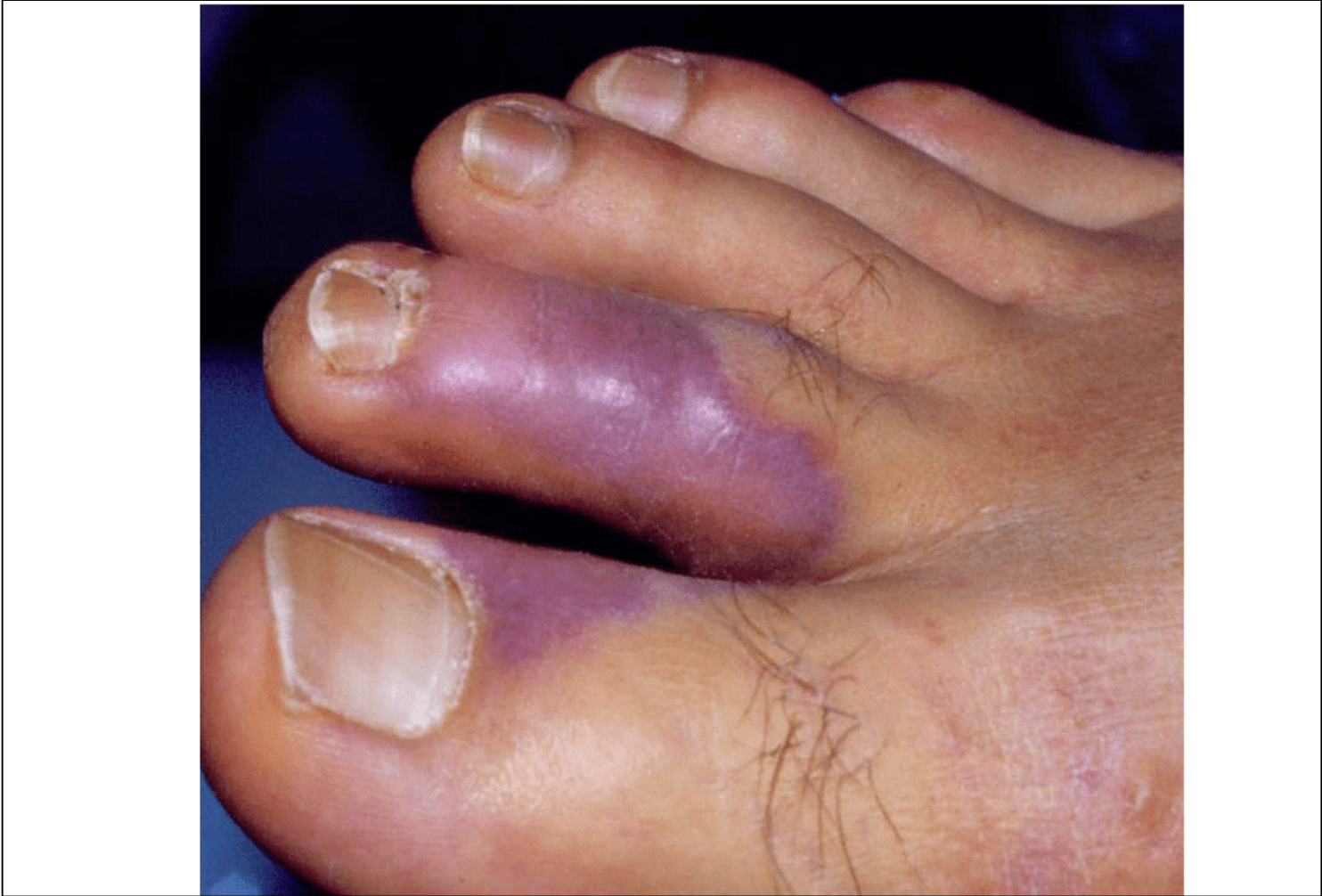

Figure 6 (Image Series) - Kaposi's Sarcoma—Cutaneous Manifestations
Image 6E: Kaposi's Sarcoma of Left Lower Extremity with Edema

Photograph credit: David H. Spach, MD

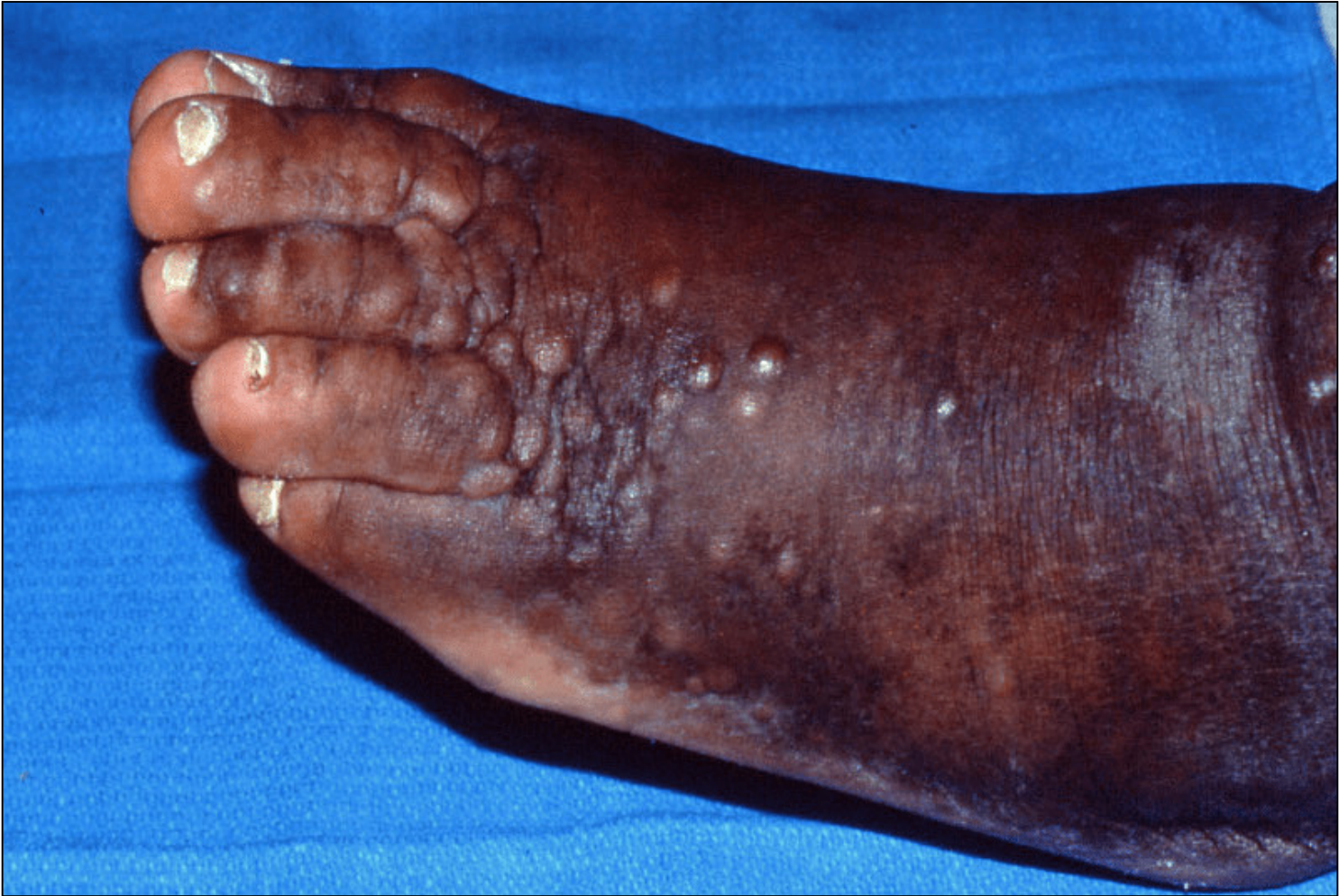

Figure 7 (Image Series) - MRSA Skin and Soft Tissue Infections (Image Series) - Figure 7 (Image Series) - MRSA Skin and Soft Tissue Infections
Image 7A: MRSA Furuncle on Left Lower Back

Photograph credit: David H. Spach, MD

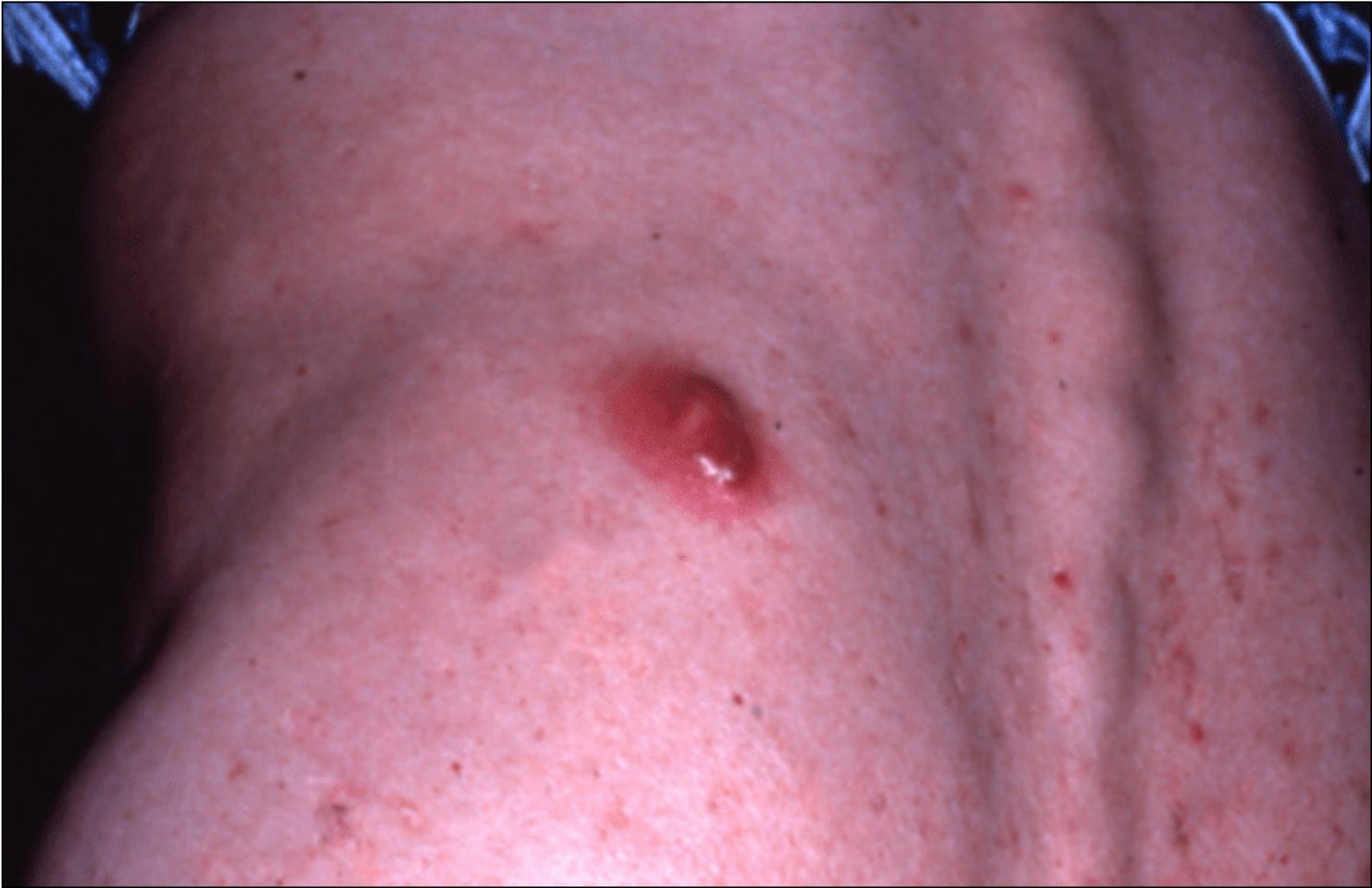

Figure 7 (Image Series) - MRSA Skin and Soft Tissue Infections
Image 7B: MRSA Abscess of Left Eyelid

Photograph credit: David H. Spach, MD

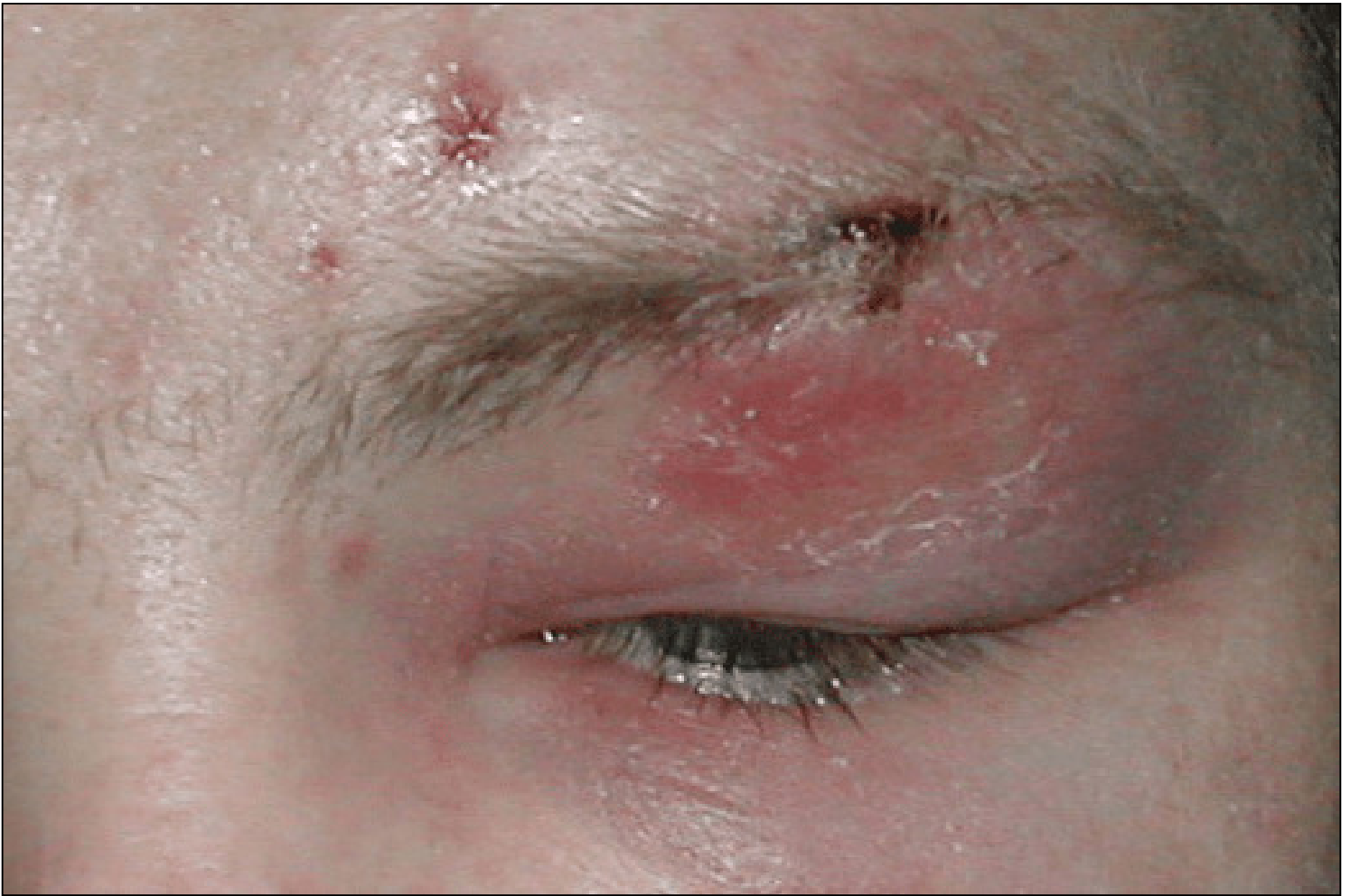

Figure 7 (Image Series) - MRSA Skin and Soft Tissue Infections
Image 7C: MRSA Abscess on Right Arm with Surrounding Cellulitis

Photograph credit: David H. Spach, MD

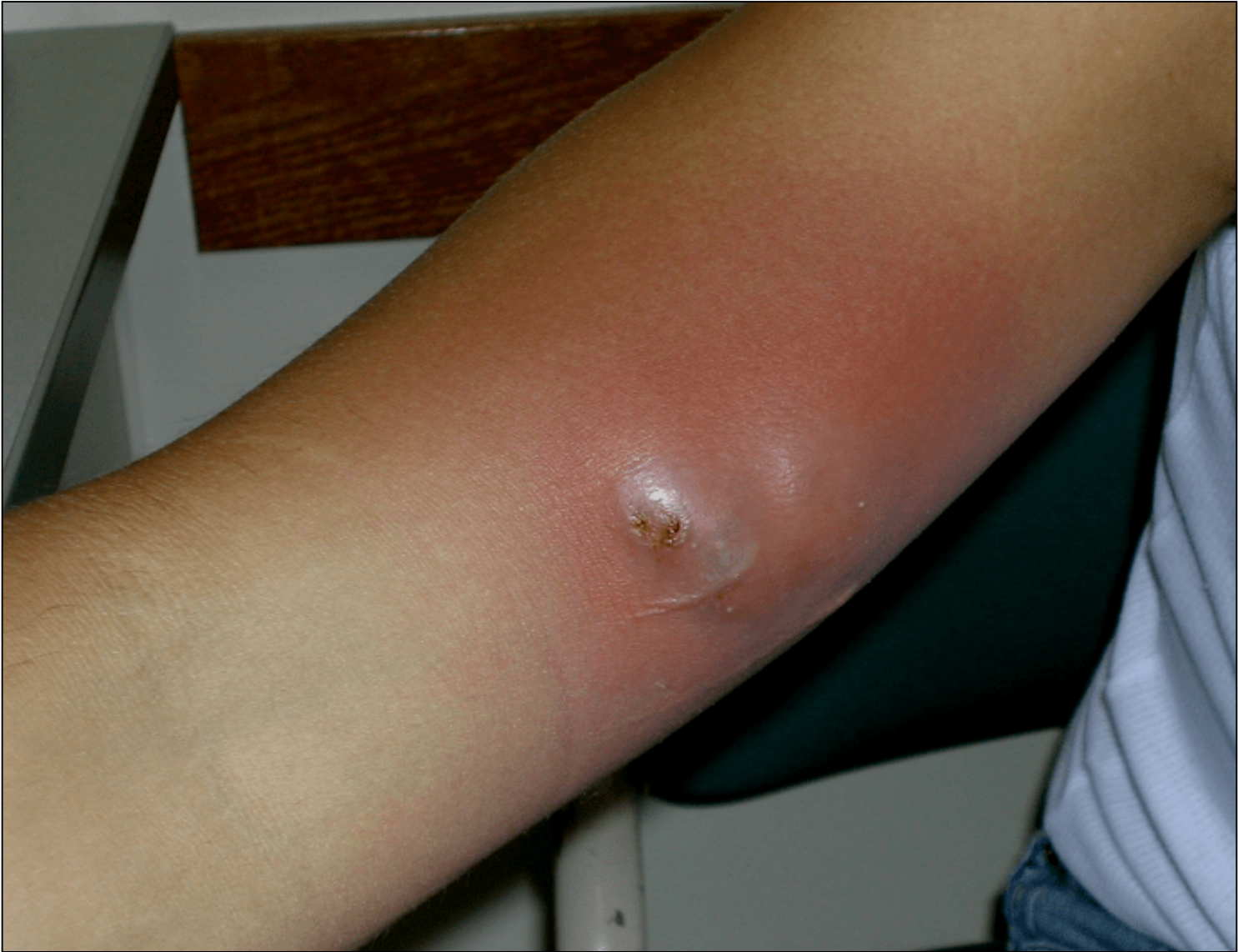

Figure 7 (Image Series) - MRSA Skin and Soft Tissue Infections
Image 7D: MRSA Lesion of Left Hand Resembling Spider Bite

Photograph credit: David H. Spach, MD

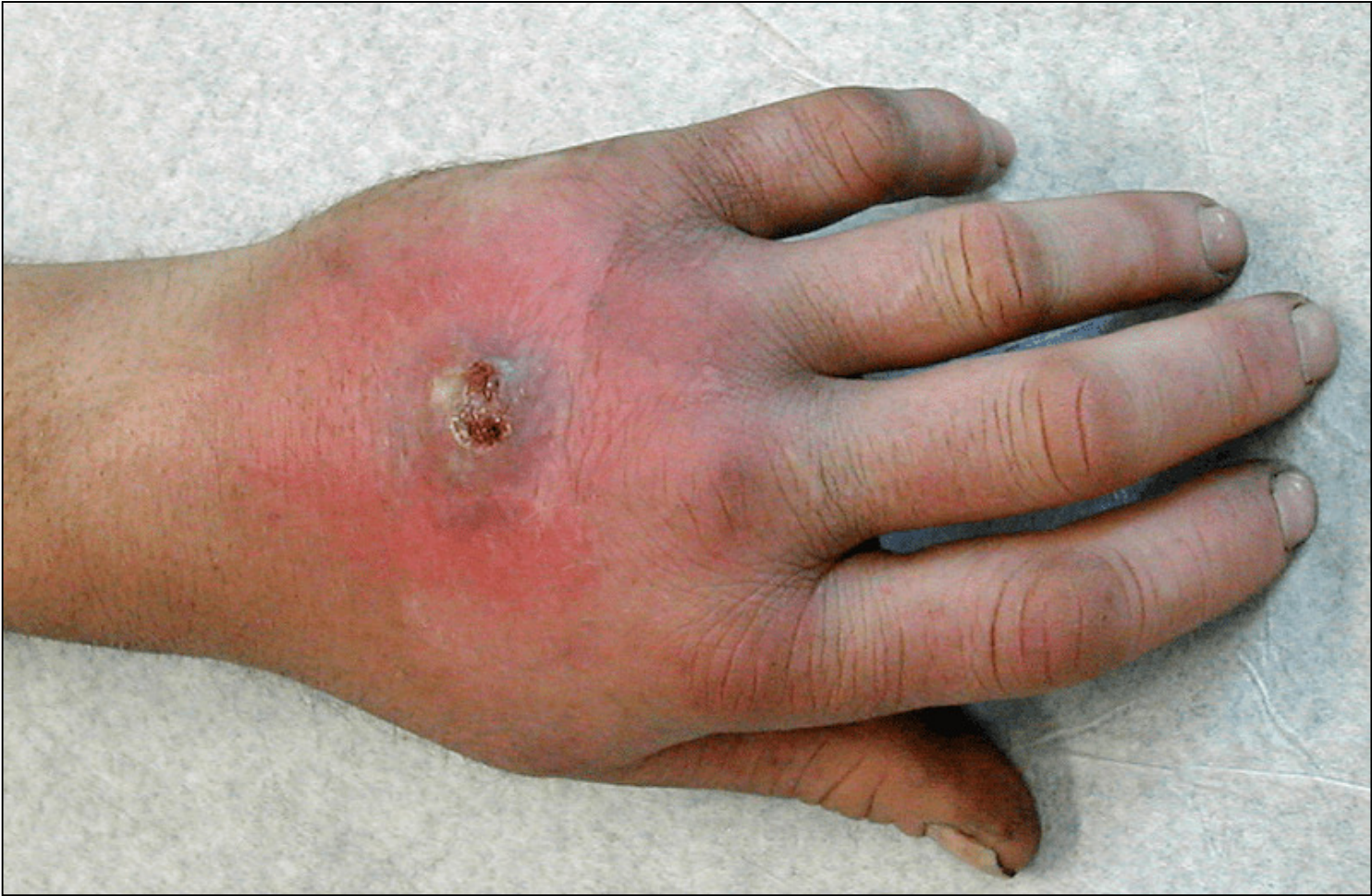

Figure 8 (Image Series) - Molluscum Cutaneous Manifestations (Image Series) - Figure 8 (Image Series) - Molluscum Cutaneous Manifestations

Image 8A: Molluscum Contagiosum—Cutaneous Lesions

Note the characteristic central umbilication of the lesions.

Photograph credit: David H. Spach, MD

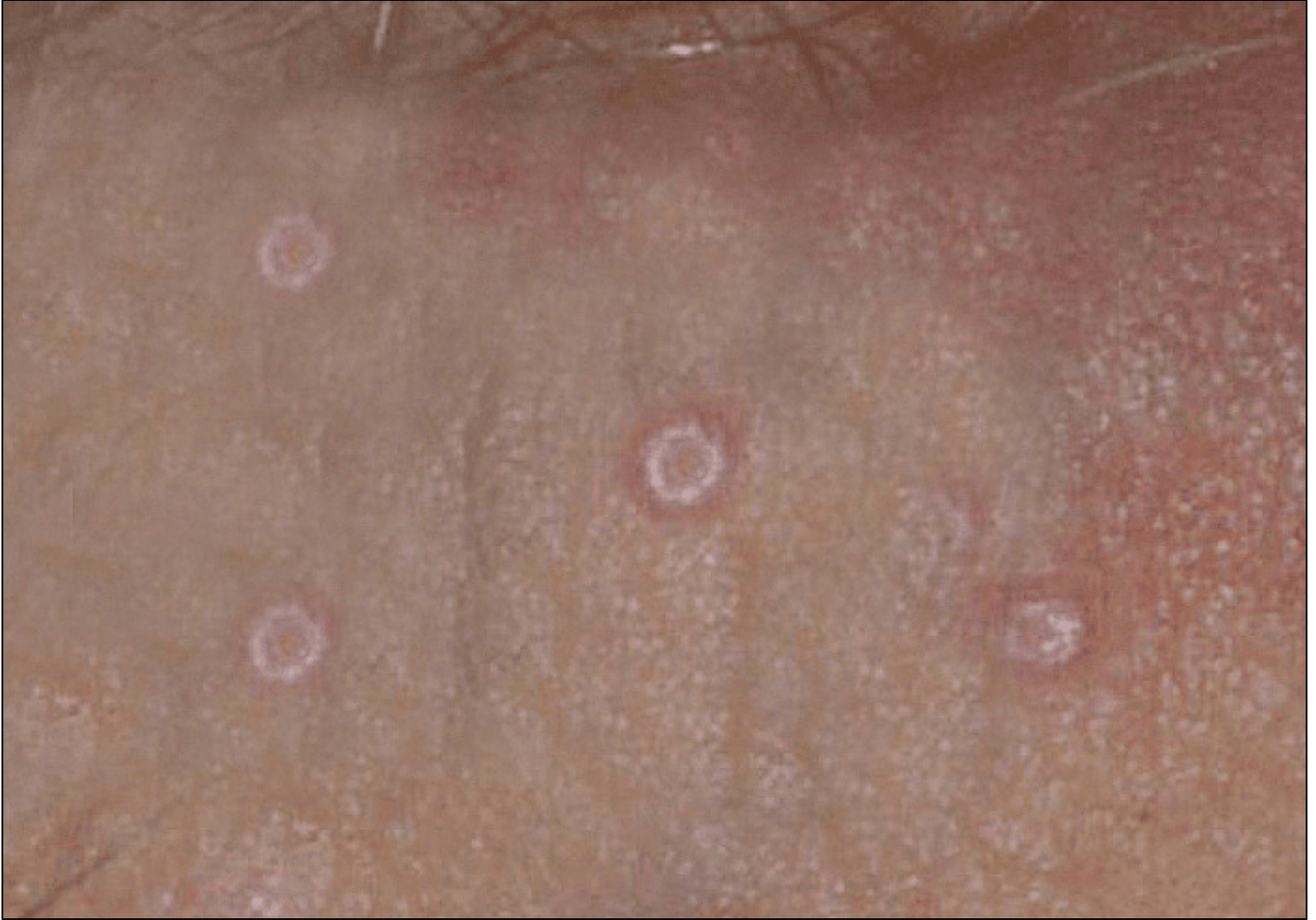

Figure 8 (Image Series) - Molluscum Cutaneous Manifestations
Image 8B: Papular Molluscum Contagiosum Lesions on Face

Photograph credit: David H. Spach, MD

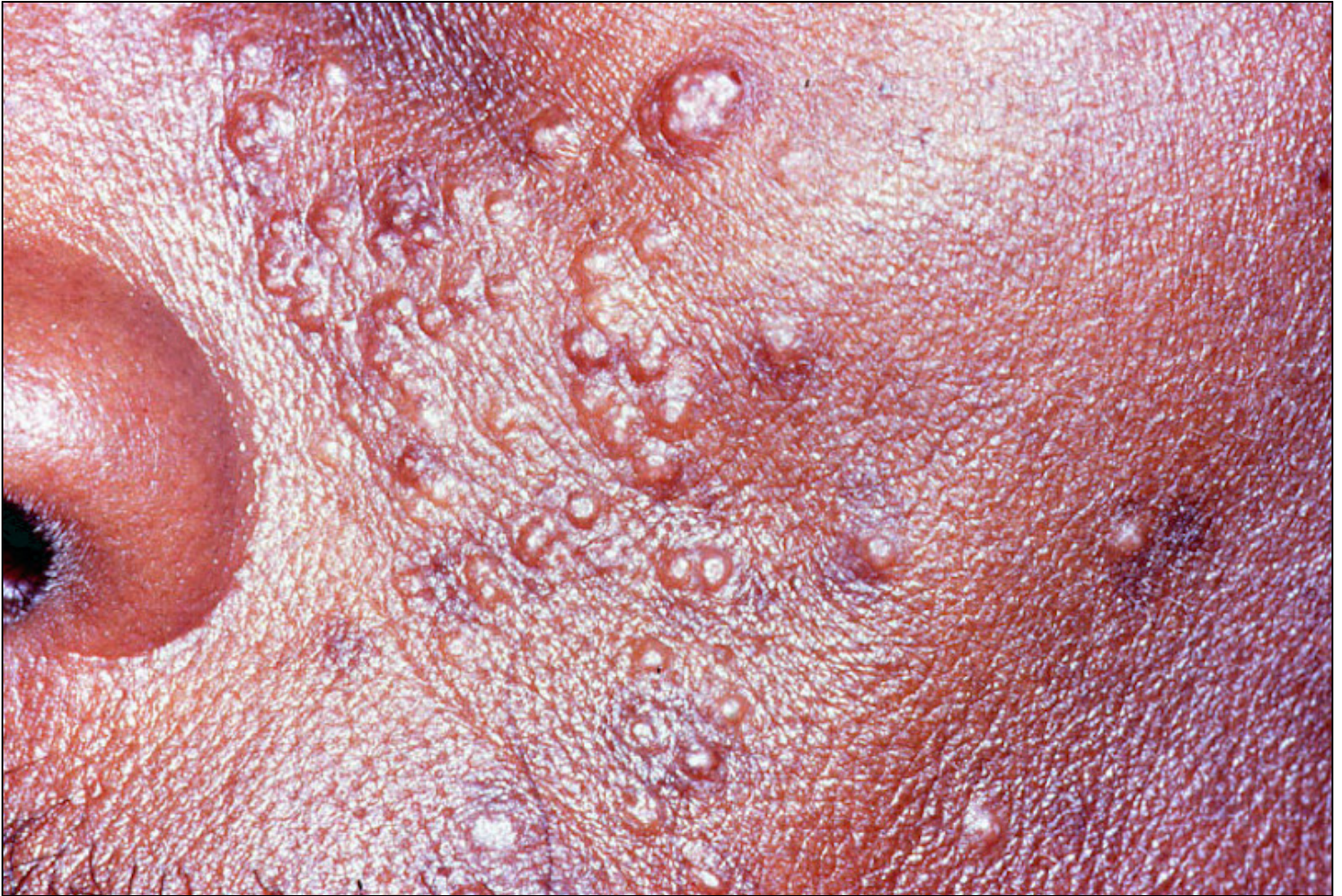


Figure 8 (Image Series) - Molluscum Cutaneous Manifestations
Image 8C: Giant Molluscum Contagiosum Lesion on Face

Photograph credit: David H. Spach, MD

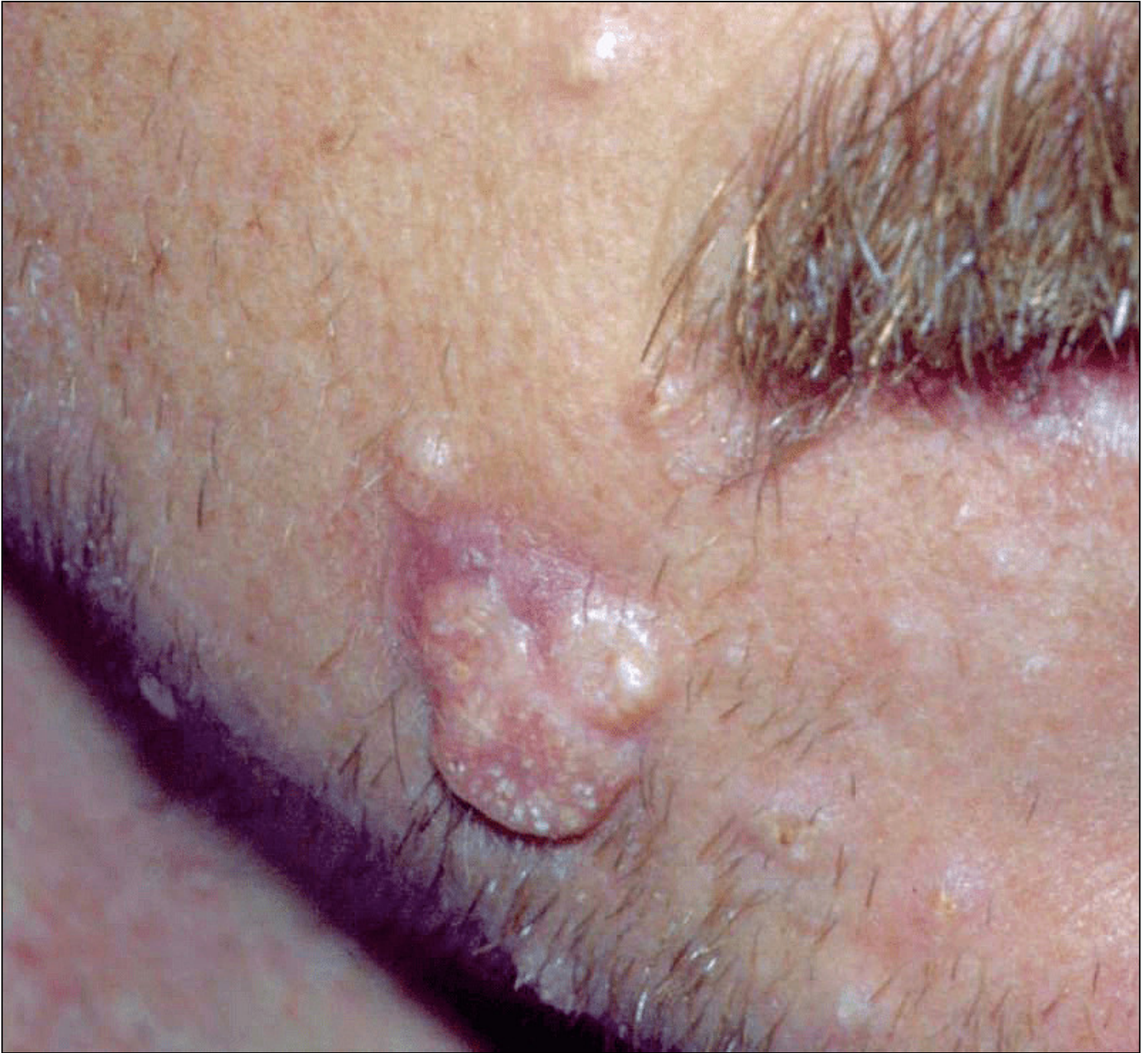

Figure 8 (Image Series) - Molluscum Cutaneous Manifestations
Image 8D: Extensive Molluscum Contagiosum Lesions on Face

Photograph credit: David H. Spach, MD

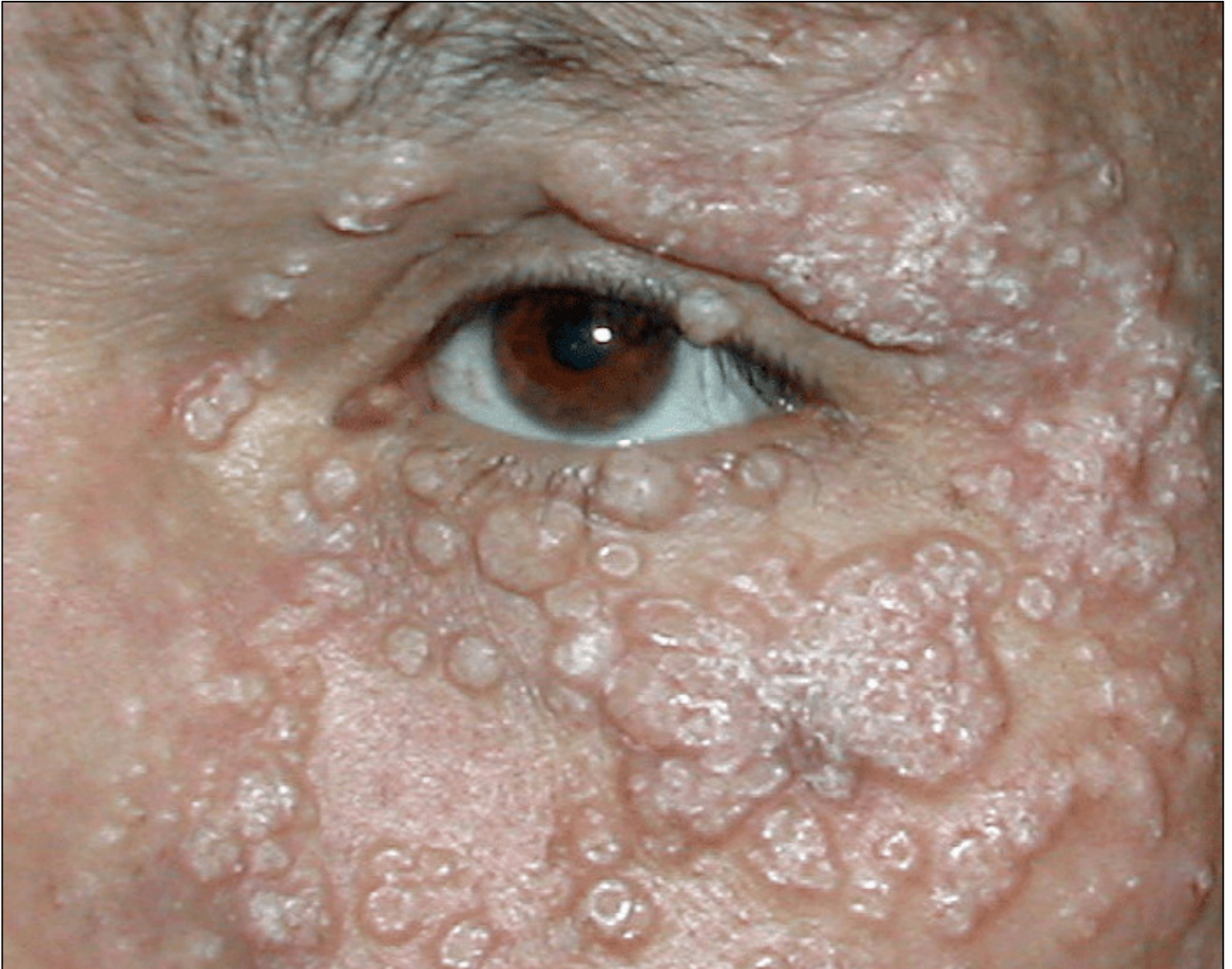

Figure 9 Histologic Appearance of Molluscum Contagiosum

This hematoxylin and eosin stained skin biopsy taken from a patient with AIDS and molluscum shows lobules of keratinocytes that contain numerous large eosinophilic intracytoplasmic inclusion bodies (Henderson-Patterson, or molluscum bodies) [arrows]. Magnification x20.

Source: Cotell SL, Roholt NS. Images in clinical medicine. Molluscum contagiosum in a patient with the acquired immunodeficiency syndrome. N Engl J Med. 1998;338:888. Reproduced with permission from the Massachusetts Medical Society. Copyright © 1998 Massachusetts Medical Society. All rights reserved.

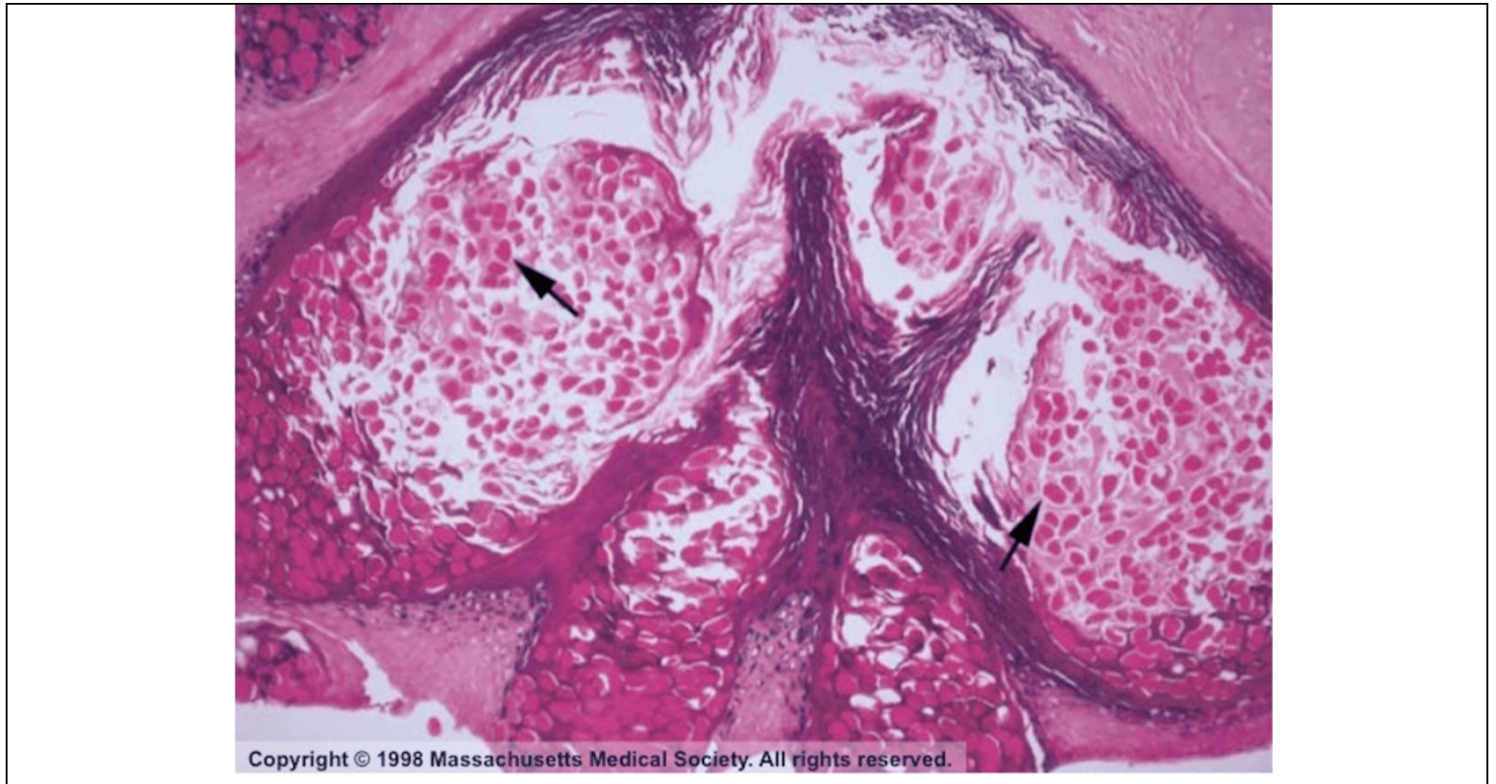


Figure 10 Extensive Erythrodermic Psoriasis on Chest and Upper Arms

This photograph was taken approximately 1 week after treatment for psoriasis was initiated and scaling of the lesions had resolved at this point of treatment.

Photograph credit: David H. Spach, MD

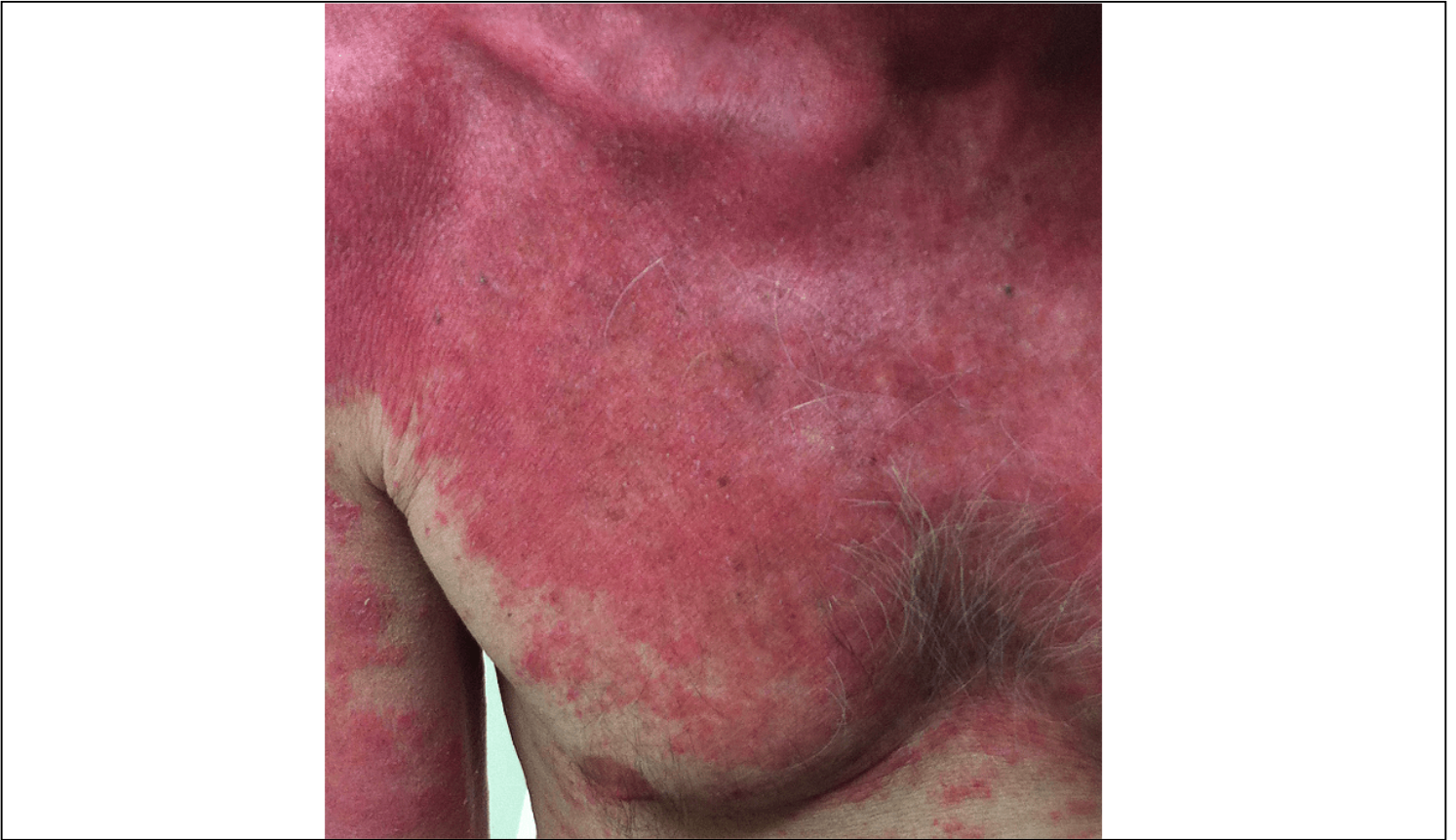

Figure 11 *Sarcoptes scabiei* Mite Viewed by Scanning Electron Microscopy

This scanning electron microscopy shows a scabies mite (*Sarcoptes scabiei* var. *hominis*) in a specimen obtained from the scraping of a woman's hand.

Source: Stoffle NN, Cohen PR. Images in clinical medicine. *Sarcoptes scabiei* infestation. N Engl J Med. 2004;350:e20. This image is reproduced with permission from the Massachusetts Medical Society. Copyright © 2004 Massachusetts Medical Society. All rights reserved.



Figure 12 (Image Series) - Crusted Scabies (Image Series) - Figure 12 (Image Series) - Crusted Scabies

Image 12A: Crusted Scabies in a Man with Advanced Immunosuppression

This image of a patient with AIDS and a CD4 count less than 100 cells/mm³ shows a diffuse erythematous rash, with plaque-like lesions in the shoulder region.

Photograph credit: David H. Spach, MD

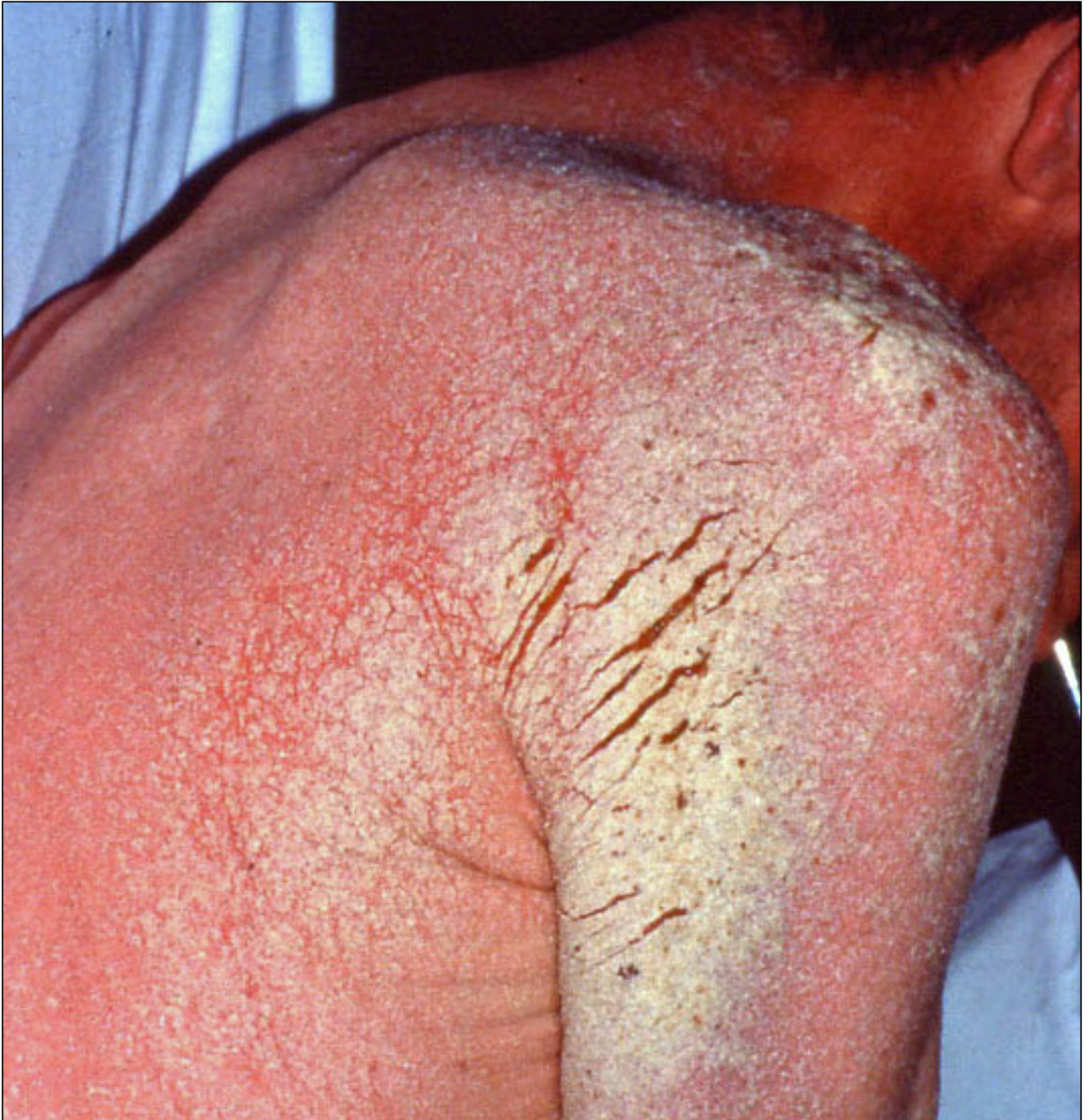

Figure 12 (Image Series) - Crusted Scabies

Image 12B: Crusted Scabies in the Scalp of a Patient with Advanced Immunosuppression

Photograph credit: David H. Spach, MD

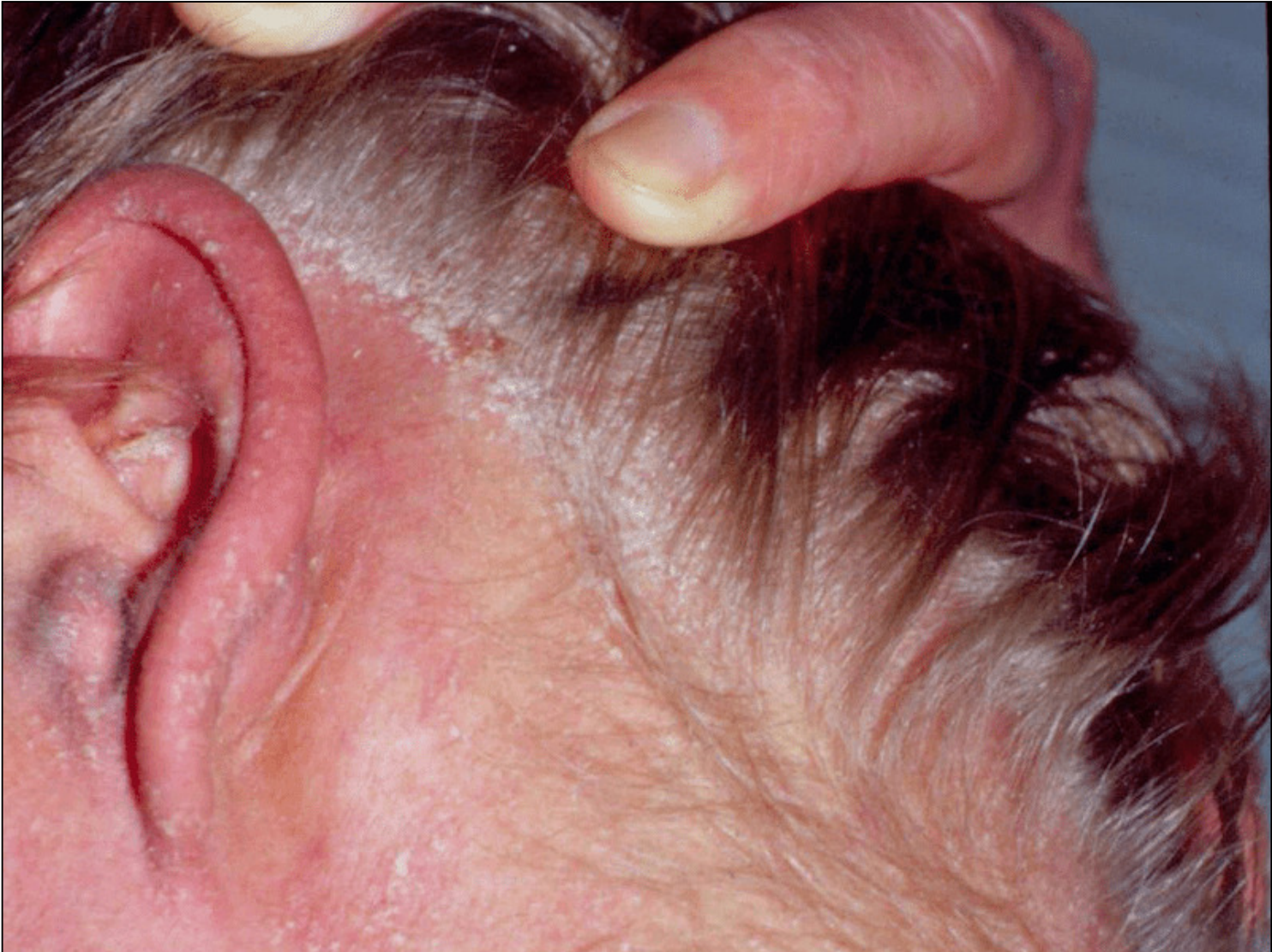

Figure 13 Scabies Mite and Eggs

Microscopy slide of skin scraping from patient with crusted scabies showing a scabies mite and multiple scabies eggs.

Source: modified from Spach DH, Fritsche TR. Images in Clinical Medicine. N Engl J Med 1994;331:777 This image is reproduced with permission from the Massachusetts Medical Society. Copyright © 1994 Massachusetts Medical Society. All rights reserved.

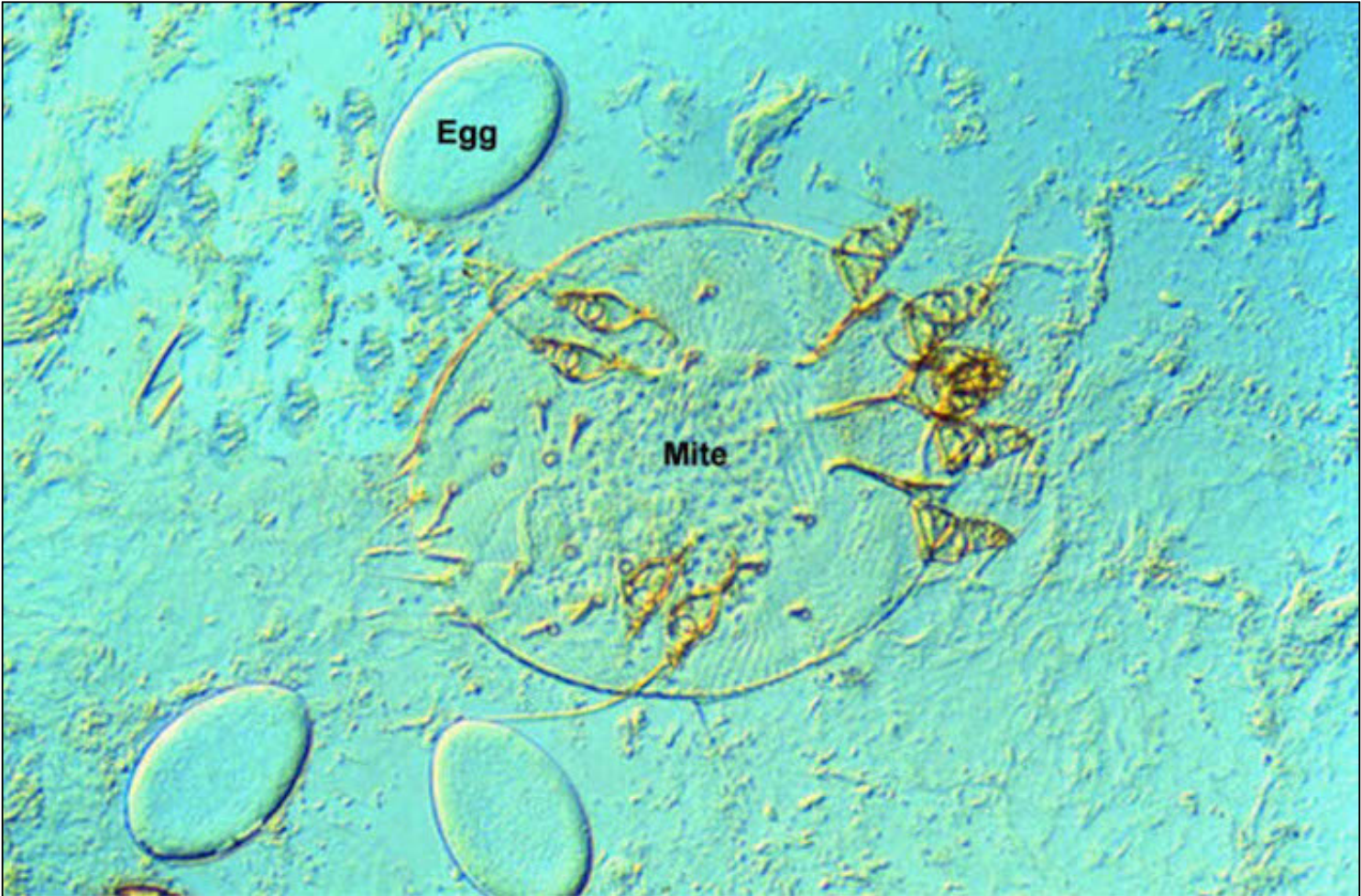

Figure 14 (Image Series) - Seborrheic Dermatitis (Image Series) - Figure 14 (Image Series) - Seborrheic Dermatitis

Image 14A: Seborrheic Dermatitis on Face with Scaling

Photograph credit: David H. Spach, MD

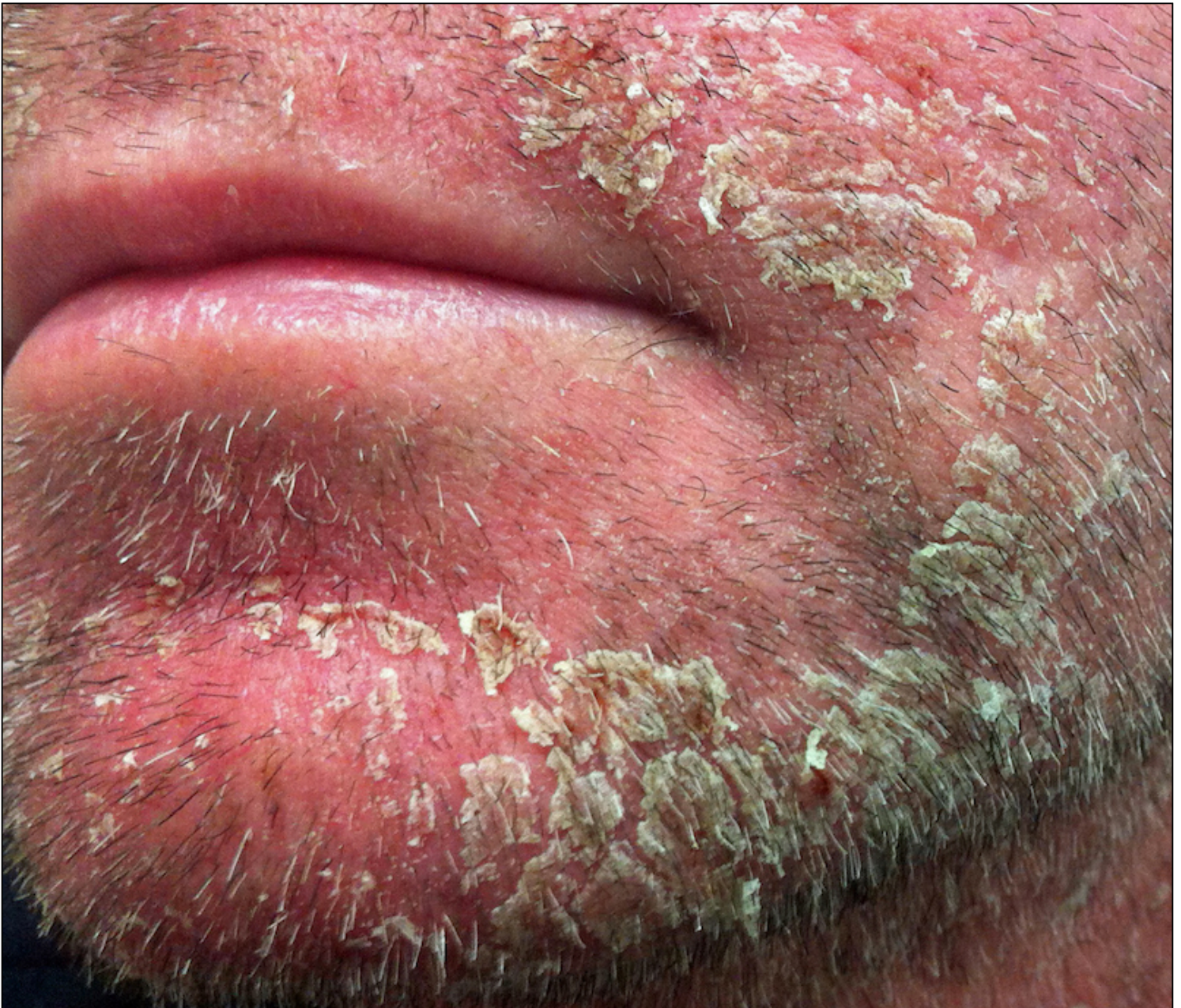

Figure 14 (Image Series) - Seborrheic Dermatitis
Image 14B: Seborrheic Dermatitis of Right Ear: Side and Rear Views

Photograph credit: David H. Spach, MD

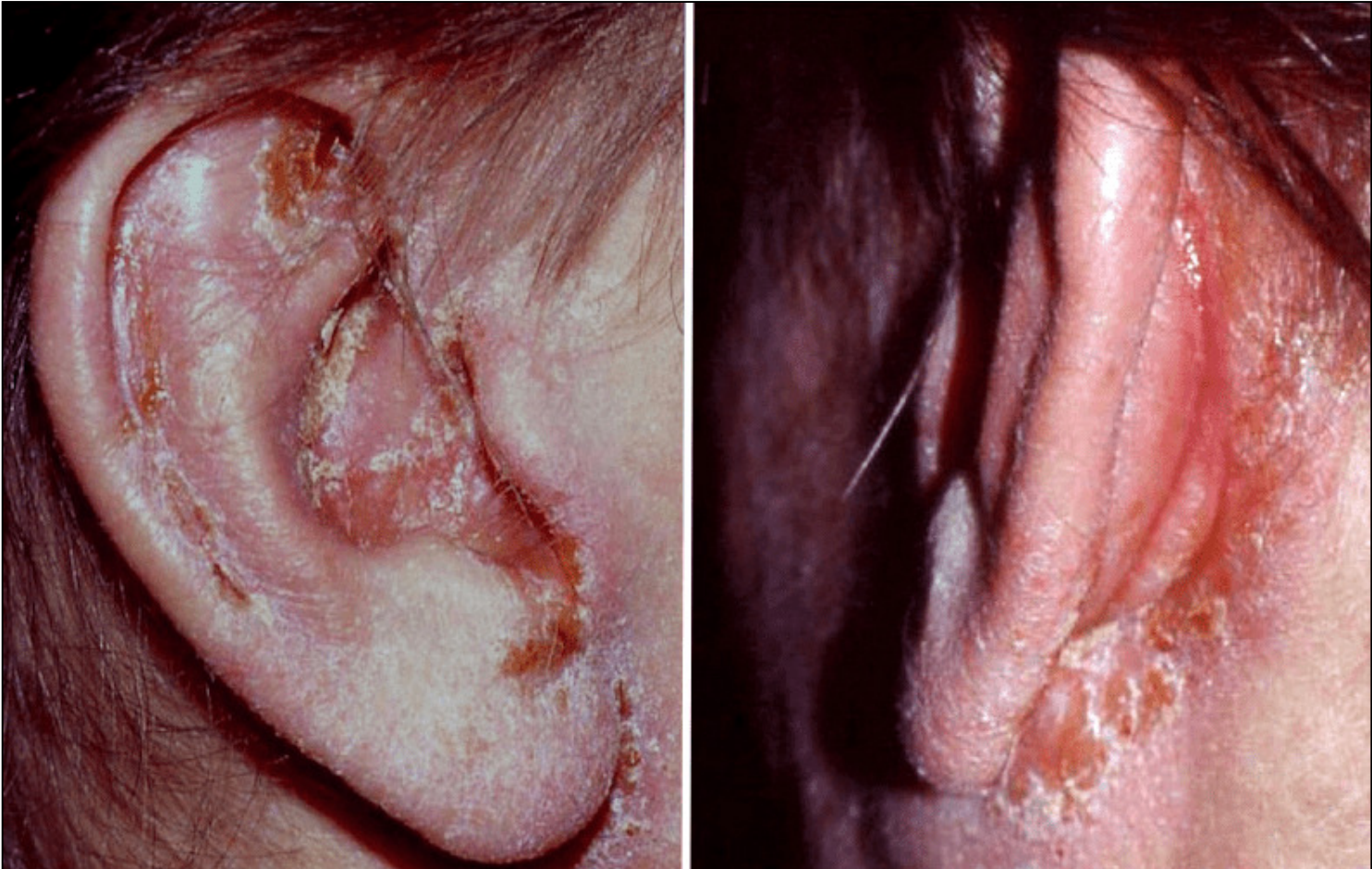


Figure 15 (Image Series) - Herpes Zoster Lesions (Image Series) - Figure 15 (Image Series) - Herpes Zoster Lesions

Image 15A: Cluster of Herpes Zoster Lesions

Note the cluster of vesicular lesions that have a surrounding erythematous base.

Photograph credit: David H. Spach, MD

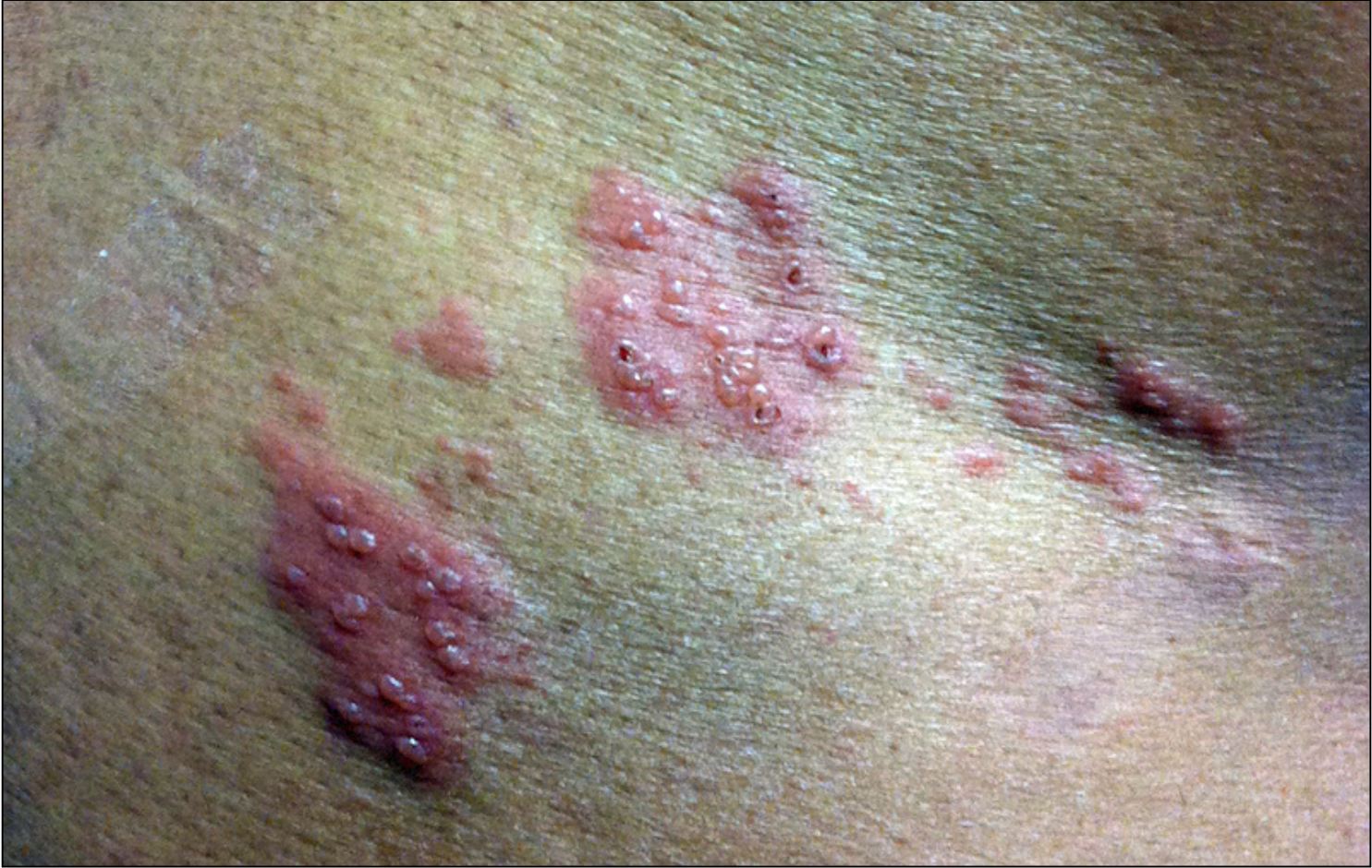

Figure 15 (Image Series) - Herpes Zoster Lesions
Image 15B: Herpes Zoster on Chest

Photograph credit: David H. Spach, MD

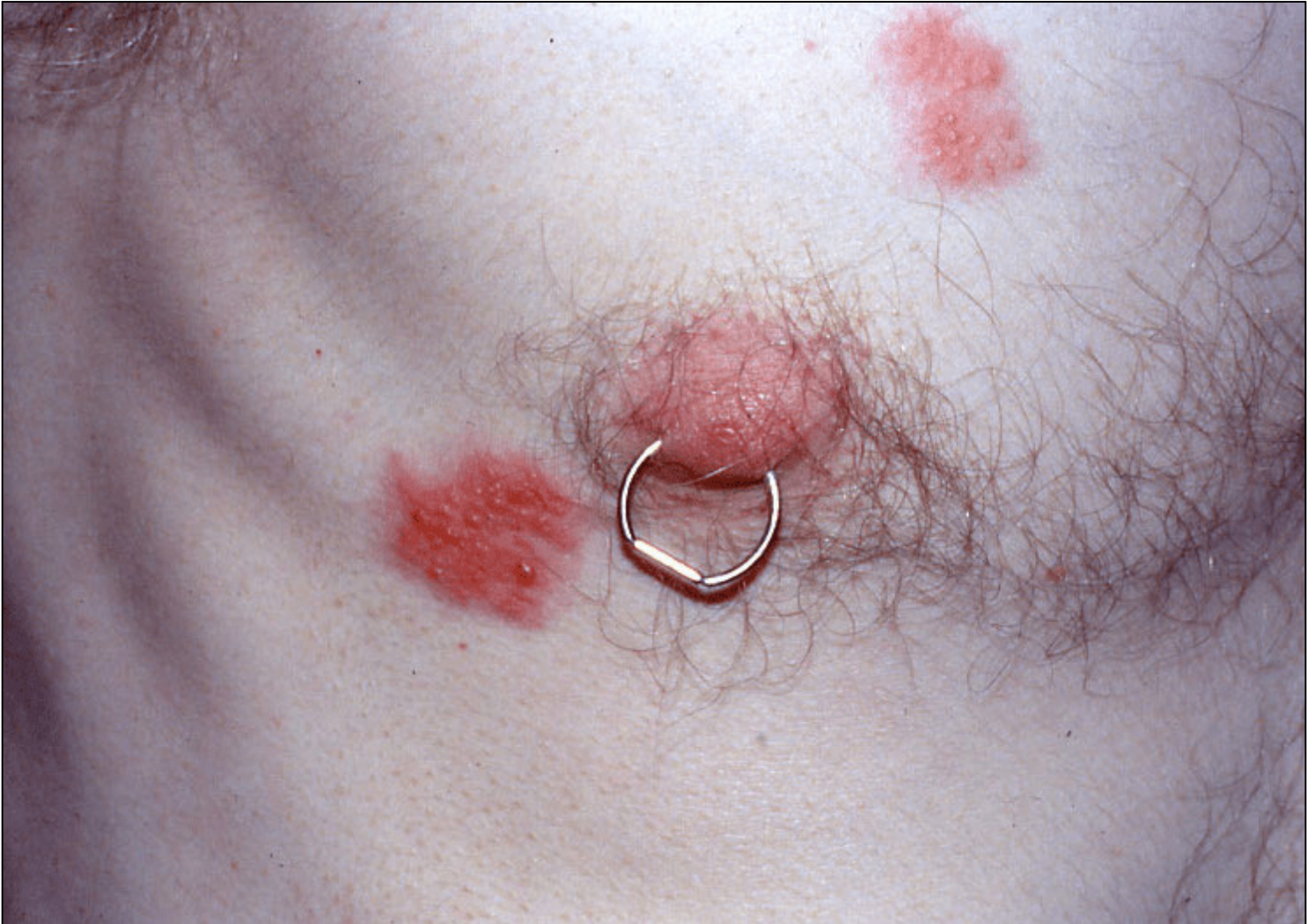

Figure 15 (Image Series) - Herpes Zoster Lesions
Image 15C: Zoster on Face with Secondary Bacterial Infection

Photograph credit: David H. Spach, MD

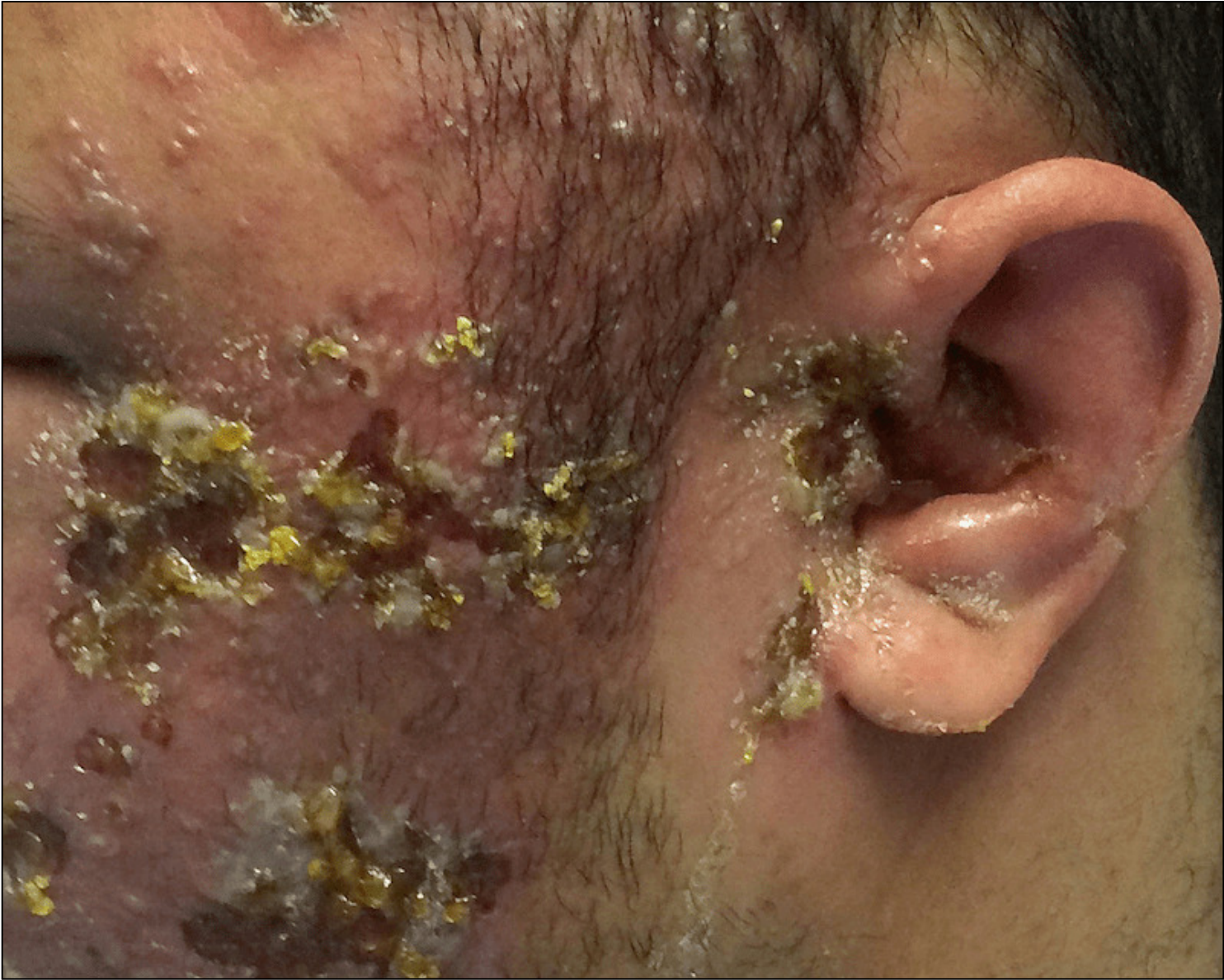

Figure 15 (Image Series) - Herpes Zoster Lesions
Image 15D: Necrotic Zoster on Thigh

Photograph credit: David H. Spach, MD

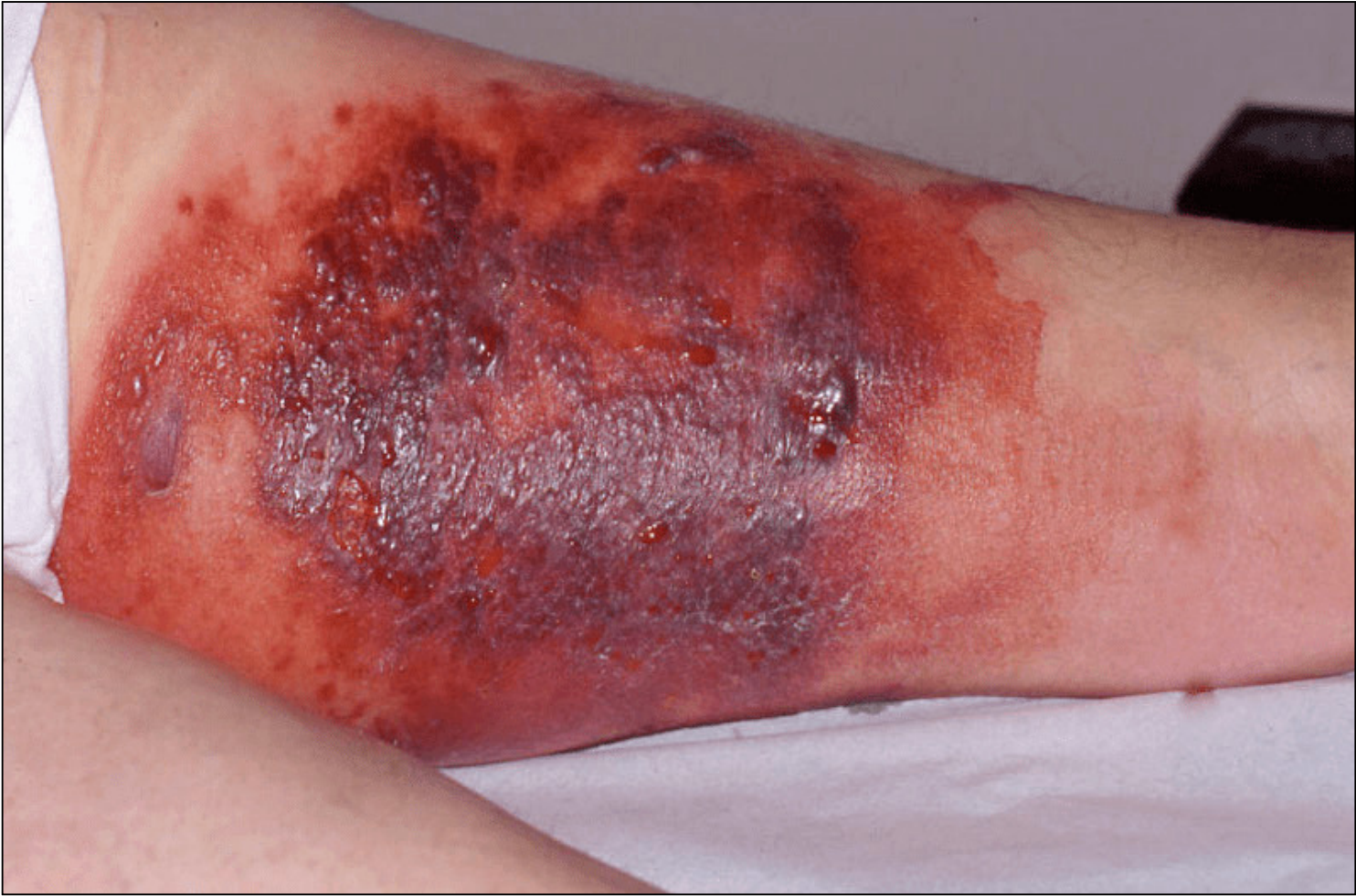

Table 1. Guidelines for the Prevention and Treatment of Opportunistic Infections in Adults and Adolescents with HIV

Recommendations for Treating Herpes Simplex Virus (HSV) Infections

Treating Genital Lesions: Initial (Duration 7-10 days) or Recurrent (Duration: 5-10 Days)

- Valacyclovir 1 g PO twice a day (AI), *or*
- Famciclovir 500 mg PO twice a day (AI), *or*
- Acyclovir 400 mg PO three times a day (AI)

Treating Severe Mucocutaneous HSV Infections (AIII)

- Initial therapy acyclovir 5 mg/kg IV q8hr
- After lesions begin to regress, change to oral therapy as above.
- Continue treatment until lesions have completely healed.

Rating of Recommendations: A = Strong; B = Moderate; C = Weak

Rating of Evidence: I = Data from randomized controlled trials; II = Data from well-designed nonrandomized trials, observational cohort studies with long-term clinical outcomes, relative bioavailability/bioequivalence studies, or regimen comparisons from randomized switch studies; III = Expert opinion

Source:

- Panel on Opportunistic Infections in Adults and Adolescents with HIV. Guidelines for the prevention and treatment of opportunistic infections in adults and adolescents with HIV: recommendations from the Centers for Disease Control and Prevention, the National Institutes of Health, and the HIV Medicine Association of the Infectious Diseases Society of America. Herpes simplex virus. Last updated: May 26, 2020. [HIV.gov]

Table 2. Guidelines for the Prevention and Treatment of Opportunistic Infections in Adults and Adolescents with HIV

Recommendations for Chronic Suppressive Therapy for Herpes Simplex Virus (HSV) Infections

Indications

- For persons with severe recurrences (AI), *or*
- Persons who want to minimize the frequency of recurrences (AI), including pregnant women, *or*
- To reduce the risk of genital ulcer disease in persons with CD4 cell counts <250 cells/mm³ who are starting antiretroviral therapy (BI)

Treatment

- Valacyclovir 500 mg PO twice a day (AI), *or*
- Famciclovir 500 mg PO twice a day (AI), *or*
- Acyclovir 400 mg PO BID (AI)

Rating of Recommendations: A = Strong; B = Moderate; C = Weak

Rating of Evidence: I = Data from randomized controlled trials; II = Data from well-designed nonrandomized trials, observational cohort studies with long-term clinical outcomes, relative bioavailability/bioequivalence studies, or regimen comparisons from randomized switch studies; III = Expert opinion

Source:

- Panel on Opportunistic Infections in Adults and Adolescents with HIV. Guidelines for the prevention and treatment of opportunistic infections in adults and adolescents with HIV: recommendations from the Centers for Disease Control and Prevention, the National Institutes of Health, and the HIV Medicine Association of the Infectious Diseases Society of America. Herpes simplex virus. Last updated: May 26, 2020. [HIV.gov]

Table 3. Guidelines for the Prevention and Treatment of Opportunistic Infections in Adults and Adolescents with HIV

Recommendations for Treatment of Herpes Zoster (Shingles)

Acute Localized Dermatomal (Duration: 7 to 10 Days; consider longer duration if lesions resolve slowly)

Preferred Therapy:

- Valacyclovir 1,000 mg PO 3 times daily (AII), *or*
- Famciclovir 500 mg PO 3 times daily (AII), *or*

Alternative Therapy:

- Acyclovir 800 mg PO 5 times daily (BII)

Extensive Cutaneous Lesions or Visceral Involvement

- Acyclovir 10 mg/kg IV every 8 hours until clinical improvement is evident (AII), *or*
- Switch to oral therapy (valacyclovir 1,000 mg three times daily, famciclovir 500 mg 3 times daily, or acyclovir 800 mg 5 times daily)—to complete a 10- to 14-day course, when formation of new lesions has ceased and signs and symptoms of visceral varicella-zoster virus infection are improving (BIII)

Rating of Recommendations: A = Strong; B = Moderate; C = Optional

Rating of Evidence: I = Data from randomized controlled trials; II = Data from well-designed nonrandomized trials, observational cohort studies with long-term clinical outcomes, relative bioavailability/bioequivalence studies, or regimen comparisons from randomized switch studies; III = Expert opinion

Source:

- Panel on Opportunistic Infections in Adults and Adolescents with HIV. Guidelines for the prevention and treatment of opportunistic infections in adults and adolescents with HIV: recommendations from the Centers for Disease Control and Prevention, the National Institutes of Health, and the HIV Medicine Association of the Infectious Diseases Society of America. Varicella-zoster virus disease. Last updated: September 7, 2022. [[HIV.gov](https://www.hiv.gov)]

